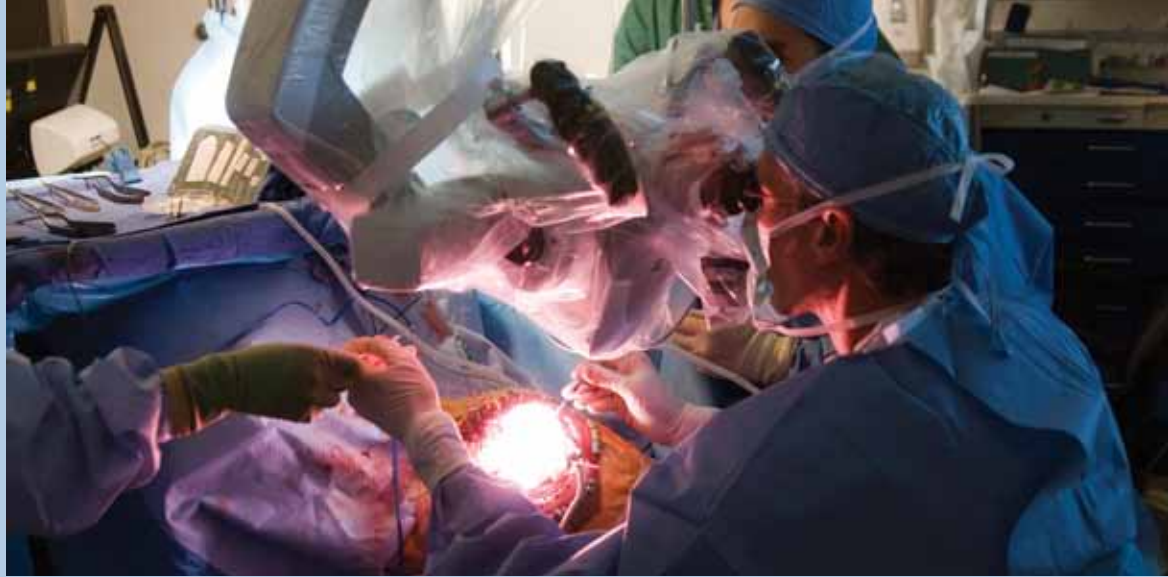
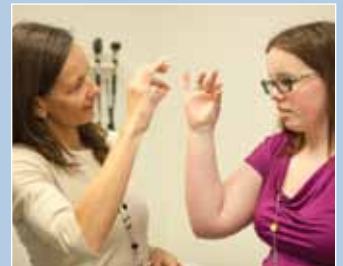
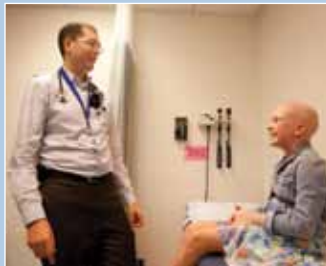The Department of Neurological Surgery at UCSF



2013 Year in Review

University of California
San Francisco
UCSF
Neurological Surgery



Contents

Letter from the Chair	2
Brain Tumor Center	3
Patient Safety & Quality Improvement	13
Brain & Spinal Injury Center	16
Vascular Neurosurgery	20
Neurospinal Disorders	23
Movement Disorders	26
Pediatric Neurosurgery	30
Center for Management & Surgery of Peripheral Nerve Disorders	33
Surgical Pain Management Program	35
Epilepsy	37

Department of Neurological Surgery

University of California, San Francisco

505 Parnassus Ave.,
Room 779 M
San Francisco, CA 94143-0112

Phone: (415) 353-7500
Fax: (415) 353-2889
neurosurgery.ucsf.edu

Design & layout:
Victoria Maier Magbilang,
Aqua Design Studio

Illustration:
Kenneth Xavier Probst

Photography:
John Branscombe, Elisabeth Fall,
Susan Merrell, and Marco Sanchez

Principal editor:
Ilona Garner
GarnerI@neurosurg.ucsf.edu

Letter from the Chair



Dear Colleagues:

Reflecting on the trends of 2013, it is clear that the push towards precision medicine will continue to reshape our treatment paradigms for diseases that affect the brain and spine in the coming year. These pages highlight the ways in which the Department of Neurological Surgery at UCSF is using the information gained from vast advances in technology to make the care for our patients increasingly personalized.

At the Brain Tumor Center, combining physiologic and metabolic imaging data with genomics is giving us a more accurate assessment of individual tumor burden to base important treatment decisions on, such as whether or not to pursue repeat surgery or treatment with a particular drug. Developing and standardizing these tools for routine clinical practice is the basis of a multi-disciplinary research program for both low-grade and high-grade brain tumors funded by Specialized Program of Research Excellence and Program Project grants from the NIH (pages 4-8).

At our Center for Surgical Movement Disorders, a team lead by Philip Starr

MD, PhD is working to integrate a new biomarker of movement disorders into the next generation of deep brain stimulators so that they respond to an individual's need for electrical pulses only when symptoms are present, similar to today's cardiac pacemakers (page 27).

At the UCSF Brain and Spinal Injury Center based at San Francisco General Hospital, Chief of Neurotrauma Geoffrey Manley MD, PhD has been pursuing a comprehensive overhaul of treatment for traumatic brain injuries. His team's efforts have recently culminated in an \$18.8 million grant to lead an international project to bring precision medicine to neurocritical care (page 12).

Maintaining our commitment to providing patients with both the most cutting-edge technologies and individualized attention again earned us a place in the nation's top five neurosurgery and neurology programs for 2013-14 by *U.S. News and World Report*. Our dedication to the best in patient care, and in working with our colleagues in community practices to make that care as seamless as possible, continues to be our highest priority.

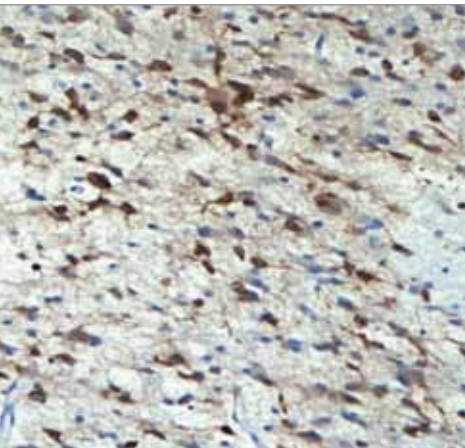
Mitchel S. Berger,
MD, FACS, FAANS

Professor and Berthold
and Belle N. Guggenhome
Endowed Chair of
Neurological Surgery

Brain Tumor Center

Specialized Program of Research Excellence for Brain Tumors

UCSF's Specialized Program of Research Excellence (SPORE) grant for brain tumor research has been continuously funded by the National Cancer Institute since 2002. The program funds four highly translational research projects that are led by teams of basic and applied science investigators who collaborate on problems of clinical significance. The UCSF Brain Tumor Research Center (BTRC) was awarded a new cycle SPORE funding in 2013.



San Francisco Bay Area Adult Glioma Survival Study (Project 1)

John Wieneke PhD, Basic Science Project Co-Leader
Margaret Wensch MPH, PhD, Applied Science Project Co-Leader

IDH-mutated astrocytoma

During the most recent phase of the UCSF Brain SPORE, neuroepidemiologists in the BTRC identified the first germline and acquired somatic genetic variations associated with survival in patients with glioblastoma (GBM). Over the next four years, the project will extend these groundbreaking

advances by identifying additional genetic variations associated with survival in patients with low-grade glioma and GBM, and by integrating survival genes identified by genome-wide association studies (GWAS) with IDH mutation and other molecular characteristics.

Patients with grade II and III tumors have substantially

longer survival times than patients with GBM, and GWAS of these lower grade tumors offer a chance to uncover new inherited factors important for survival. This research team will also apply these results to long-standing completed clinical trials to begin to assess the generalizability of their findings to clinical trial populations.

Faculty

Adult Neuro-Oncology

Nicholas Butowski MD
Susan Chang MD
Jennifer Clarke MD, MPH
Michael Prados MD

Adult Brain Tumor Surgery

Manish Aghi MD, PhD
Mitchel Berger MD
Sandeep Kunwar MD
Michael McDermott MD
Philip Theodosopoulos MD

Neuropsychology

Caroline Belkoura PhD

California Center for Pituitary Disorders

Manish Aghi MD, PhD
Lewis Blevins, Jr. MD
Sandeep Kunwar MD
Philip Theodosopoulos MD

Research Laboratories

Manish Aghi MD, PhD
Oncolytic viral therapies;
vascular biology of glioma
Arturo Alvarez-Buylla PhD
Developmental neuroscience;
stem cell biology

Krystof Bankiewicz MD, PhD
Drug delivery strategies;
gene therapy

Arnau Benet MD
Surgical anatomy; novel surgical approaches

Mitchel Berger MD
Brain mapping; molecular and genetic basis of brain tumors

Gabriele Bergers PhD
Angiogenesis;
tumor invasion

Soonmee Cha MD
Neuroimaging

Joseph Costello PhD
Functional genomics

Nalin Gupta MD, PhD
Pediatric brain tumors;
cell-cell interactions

Daphne Haas-Kogan MD
Cell signaling; genetic mutations; therapeutic irradiation enhancement

C. David James PhD
Molecular biology of CNS cancers; rodent model testing of experimental therapeutics

Annette Molinaro MA, PhD
Biostatistics and Computational Biology

Claudia Petritsch PhD
Brain cancer stem cells; asymmetric stem cell division; novel tumor suppressor genes

Arie Perry MD
Neuropathology; molecular genetic markers of tumorigenesis and malignant progression

Joanna Phillips MD, PhD
Neuropathology; interaction between tumor cells and the microenvironment

Russell Pieper PhD
Signal transduction; models of human gliomagenesis and drug resistance

David Rowitch MD, PhD
Central nervous system development; Tumorigenesis

William Weiss MD, PhD
Mouse models of human brain tumors; cell signaling

Kyle Walsh PhD
Genetic and molecular neuroepidemiology

John Wiencke PhD
Biomarker development and application in brain tumor etiology

Margaret Wrensch MPH, PhD
Genetic and molecular epidemiology of adult glioma

Shichun Zheng PhD
Molecular neuroepidemiology

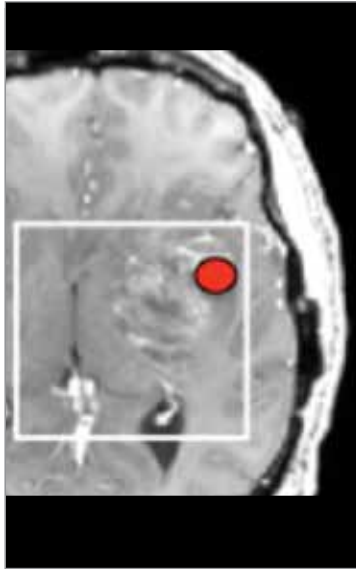


Image-guided biopsies are performed to correlate anatomical image findings with metabolic findings. The red dot on a T1-weighted MR image with gadolinium shows where the tissue sample was obtained.

Novel Biomarkers of Malignant Progression in Recurrent Low-Grade Glioma (Project 2)

Susan Chang MD
Clinical Project Co-Leader

Joseph Costello PhD
Basic Science Project Co-Leader

Sarah Nelson PhD
Basic Science Project Co-Leader

Project 2 is focused on identifying noninvasive imaging parameters as biomarkers of malignant transformation in diffuse low-grade glioma and to use these parameters to select regions for characterizing the genetic mutations associated with recurrent disease. The studies will have a significant impact on the management of these patients by providing objective criteria to predict when a lesion transforms to a more malignant phenotype, whether and where to intervene surgically, and how to select the next-line therapy.

This is an important problem because patients with tumors that recur from a prior low-grade glioma have different outcomes depending on

histological subtype, grade, and molecular/cytogenetic features. The mechanisms of malignant transformation are unclear and treatment strategies are often pursued without histological confirmation of recurrent tumor.

Neuroimaging specialists are using state-of-the-art spectroscopic techniques to directly assess the ability of spectroscopic markers to predict time to progression and overall survival in low-grade glioma patients. The project also includes a first-ever analysis of the genetic mutations that drive low-grade glioma formation and progression and which may serve as biomarkers of the disease.

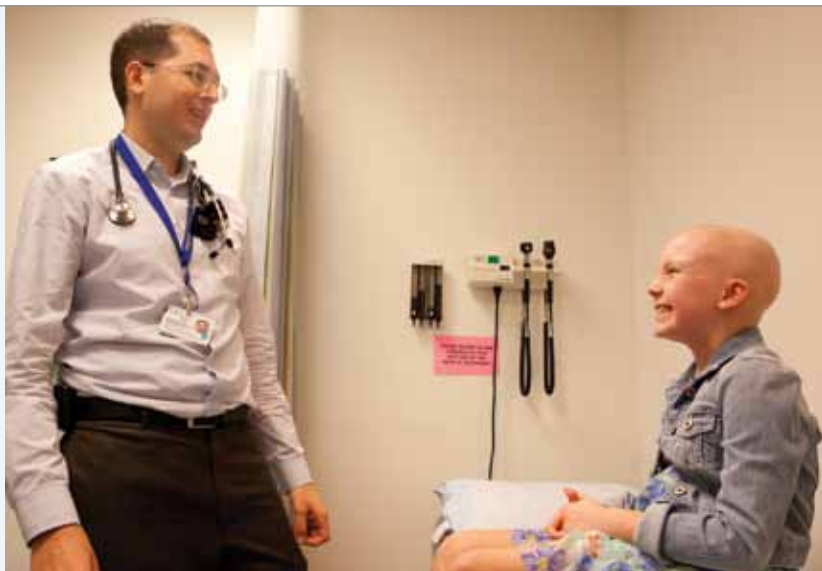Novel Approaches for Improving Pediatric BRAF^{V600E} Glioma Patient Outcomes (Project 3)

C. David James PhD
Basic Science Project Co-Leader

Michael Prados MD
Clinical Project Co-Leader

Theodore Nicolaides MD
Clinical Project Co-Leader

Pediatric neuro-oncologist Theodore Nicolaides MD is leading a new clinical trial of the drug vemurafenib for pediatric glioma. Preclinical studies show vemurafenib to be effective against tumors with the BRAF^{V600E} mutation.



Other than surgery and radiation, there are currently no effective treatments for glioma in children. Available treatments only provide short-term relief from the cancer, while substantially contributing to patient morbidity.

This SPORE project is based on work by BTRC investigators showing that

a large fraction of pediatric brain tumors contain a mutation in the gene encoding BRAF – called the BRAF^{V600E} mutation. In preclinical studies, the mutation was shown to sensitize these tumors to clinically available mutant BRAF inhibitors and mutant BRAF/cyclin-dependent kinase inhibitor combinations.

Over the next four years, the investigators will address mechanistic aspects of inhibitor action; will initiate pre-clinical studies comparing the efficacy of mutant BRAF inhibitors in combination with different mechanism-based signaling inhibitors; and will initiate clinical trials of mutant BRAF inhibitors alone and

in combination with other agents. The first clinical trial will be investigating the BRAF inhibitor vemurafenib. This is the first pediatric project of any NIH SPORE program for brain tumors.

Overcoming Local and Peripheral Immune Suppression in Glioma to Facilitate Effective Glioma Therapy (Project 4)

Andrew T. Parsa MD, PhD
Clinical Project Co-Leader

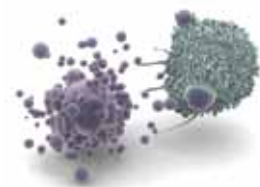
Russell O. Pieper PhD
Basic Science Project Co-Leader

This innovative immunology project builds on findings from our previous cycle of SPORE funding that identified key factors contributing to the failure of vaccine-based therapies in brain tumors. BTRC investigators demonstrated that the protein B7-Homologue 1 (B7-H1), which is expressed on the

glioma cell surface, induces CD8+ T-cell apoptosis and is positively regulated by PI(3)K. Going forward, the goals of the project are to: determine the impact of the PI(3)K/Akt/mTOR/B7-H1 pathway on expansion of regulatory T-cells and locally suppressive macrophages; investigate the utility of inhibiting PI(3)K/Akt/

mTOR/B7-H1 as a means of augmenting immunotherapy in the pre-clinical setting; and initiate a first of its kind, NCI cooperative group-sponsored, large-scale phase II clinical trial to examine the impact of PI3K activation and B7-H1 expression on response to active immunotherapy in patients with recurrent GBM.

Final stage of apoptosis

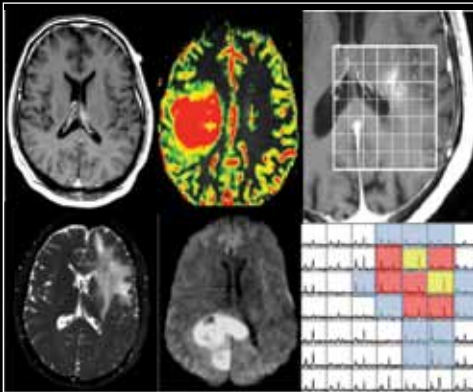


Apoptotic cell White blood cell

Program Project Grant

This year marked the eighth cycle of Program Project Grant funding for the Brain Tumor Research Center from the NIH. The BTRC's first Program Project Grant was awarded in 1979 to study the biology and therapy of malignant brain tumors. One of the biggest challenges that still exists in clinical neuro-oncology is to accurately assess tumor burden both in newly diagnosed and post-treated glioblastoma. There is a great need to establish biomarkers of biological behavior that can be used to guide treatment decisions. For the next four years, the program will focus on three projects that integrate imaging and tissue correlates to optimize the management of patients with glioblastoma.

6



Improved Management of Glioblastoma by Integrated Imaging and Tissue Analysis

Principal Investigator: Sarah Nelson PhD

Standard anatomic imaging and examples of metabolic/physiologic MR imaging techniques – perfusion, spectroscopy, T2 quantification, and diffusion-weighted imaging.

The previous cycle of the BTRC Program Project Grant was focused on determining which noninvasive metabolic and physiological imaging parameters are valuable for characterizing newly diagnosed and post-treatment glioblastoma (GBM) and to link these metrics with ex vivo metabolic profiles and histological characteristics. Diffusion-weighted imaging,

perfusion imaging, and MR spectroscopy parameters can provide useful information on tumor burden and response to treatment.

Over the next cycle of the Program Project Grant, investigators will validate the metrics defined in the previous funding cycle and begin applying them to routine clinical practice. These metrics include the myoinositol/

choline index derived from MR spectroscopy, which was shown to be a relevant biomarker for gliosis. More than 250 patients with newly diagnosed and post-treated glioblastoma have been enrolled in image-guided biopsy studies to correlate histologic, genomic, and metabolic characteristics with physiological imaging features.

Image-Guided Genomics to Understand Tumor Heterogeneity and Evolution

Principal Investigators: Susan Chang MD and Joseph Costello PhD

The goal of this investigation is to evaluate newly diagnosed and post-treated glioblastoma with specific emphasis on the genomic features of tumor heterogeneity and evolution. Changes in the tumor from time of initial diagnosis to progression occur at the molecular level – both as part of the natural history of the

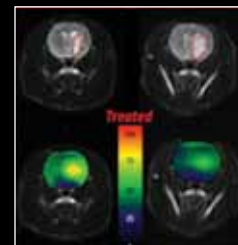
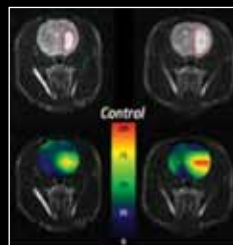
disease and as an effect of therapies. Determining the genetic changes at the time of progression and correlating them to physiologic and metabolic imaging could more accurately reflect the biological behavior of recurrent glioblastoma. The information gleaned from these studies will be especially useful for

evaluating agents that target specific dysregulated pathways within a given tumor. If the activated pathways change from initial diagnosis to recurrence, patients will need to be enrolled in new protocols that are appropriate for the new molecular signature of their tumor.

Hyperpolarized ^{13}C MRSI Monitoring of Pyruvate Metabolism to Assess Drug Action

Principal Investigators: Russell Pieper PhD and Sabrina Ronen PhD

Anatomical images and heatmaps of Lac/Pyruvate at day 0 and 7 for control and treated rats illustrating a significant decrease in Lac/Pyruvate at day 7.



The final group of experiments in the BTRC Program Project Grant explores ex vivo, in vivo, and clinical development of hyperpolarized ^{13}C imaging as a biomarker of drug delivery and response to therapy. UCSF is one of the only institutions with this technology and this study will represent the first-ever application of hyperpolarized ^{13}C imaging to patients with brain tumors.

Preliminary studies in glioblastoma models indicate that response to

therapeutic agents such as temozolomide, PI3K/mTOR inhibitors, and histone deacetylase inhibitors is associated with a drop in the activity of enzymes involved in pyruvate metabolism, including pyruvate kinase and lactate dehydrogenase. This manifests in a tumor-specific decrease in the conversion of hyperpolarized ^{13}C pyruvate to ^{13}C lactate and a drop in the ratio of hyperpolarized lactate to pyruvate (Lac/Pyruvate) detectable by ^{13}C MRS and MRSI within the first week of treatment. Hyperpolarized

^{13}C Lac/Pyruvate may therefore serve as a novel biomarker of response to therapy and could allow clinicians to rapidly assess early response to treatment and make critical decisions regarding changes in drug therapy faster.

Clinical evaluation of hyperpolarized ^{13}C imaging will be performed in conjunction with the first project funded by the Program Project Grant, which is vetting new imaging parameters in clinical studies.



UCSF's Brain Tumor Center Launches the Gordon Murray Caregiver Program to Support Families of Patients with Brain Tumors

This year UCSF launched a new program to provide more support for family members who are often overwhelmed by the emotional toll and responsibilities that come with caring for loved ones with brain tumors. From initial diagnosis of a brain tumor, patients and families will receive personalized assistance from a dedicated caregiver team over the trajectory of the illness. Team members are trained to work with caregivers on specific topics at each stage of the illness. A series of pre-determined checkpoints for interviews with the patient

and caregiver ensures that all needs are being met in a timely manner. The goal is to support caregivers so that they are prepared to help their loved ones through the illness and, in turn, optimize the quality of life for patients during this difficult time.

The Gordon Murray Caregiver Program is named in honor of Gordon Murray who was treated at UCSF and lost his battle with brain cancer. Grateful for the state-of-the-art care that he received at UCSF, Mr. Murray's wife Randi Murray lead a fundraising campaign to

build a program that helps families get the resources they need throughout the difficult experience of diagnosis, treatment, and bereavement. She was joined by philanthropists Cathy and Mike Podell and Marritje and Jamie Greene in helping to raise over \$2 million for establishing the Gordon Murray Caregiver Program and the construction of additional laboratories at the Brain Tumor Research Center.

Find out more at:
support.ucsf.edu/gordonmurrayprogram.

UCSF Neuro-Oncology Director to Serve as Editor-in-Chief of a New Scientific Journal Dedicated to Applied Neuro-Oncology

Oxford University Press and the Society for Neuro-Oncology will be publishing a new journal, *Neuro-Oncology Practice*, beginning in 2014. The new journal will be edited by Susan Chang MD, Director of the Division of Neuro-Oncology at UCSF.

Neuro-Oncology Practice will cover applied neuro-oncology, filling a unmet need for more practical and educational content. This new journal will also provide the multidisciplinary

field of neuro-oncology professionals, such as physicians, nurses, physical and occupational therapists, palliative care specialists, and neuropsychologists, with clinical information to enhance patient care, quality of life, psycho-social support, and management of co-morbid conditions.

Some of the aims of *Neuro-Oncology Practice* include:

- To apply new trial results to improve standards of patient care

- To translate scientific advances, such as tumor molecular profiling and advanced imaging, into clinical treatment decision-making and personalized brain tumor therapies

- To raise awareness of basic, translational, and clinical research in areas of symptom management, survivorship, neurocognitive function, end-of-life issues, and caregiving.

Neuro-Oncology Practice will be the sister journal to *Neuro-Oncology*, the

official journal of the Society of Neuro-Oncology, which Oxford University Press has published since 2010. Interest in creating the journal arose from a popular supplement in *Neuro-Oncology*, edited by Dr. Chang, which was devoted to issues of patient care and quality of life. For more information about the journal, visit: www.oxfordjournals.org/our_journals/nop.

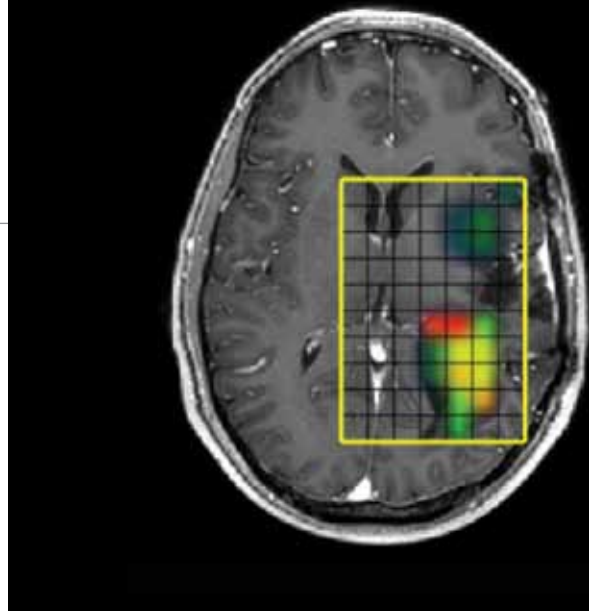
Evolution of Glioma from Low-Grade to High-Grade Follows Distinctive Genetic Paths and Some Low-Grade Tumors are Transformed by Temozolomide

For patients with low-grade glioma, there is no standard treatment regimen beyond surgery. It has been clearly shown that a greater extent of resection can improve time to progression and survival for these patients, but there is little consensus on the role of chemotherapy following surgery. Many patients with low-grade gliomas are offered the chemotherapeutic agent temozolomide (TMZ), which is the standard of care for patients with high-grade glioma, in the hopes that it may also be efficacious in that patient population.

While patients with low-grade gliomas have a median survival of seven years, the tumors almost always recur, eventually as a more malignant tumor type. How the tumors evolve from low-grade to high-grade has been an intense area of study for genomics expert and BTRC principal investigator Joseph Costello PhD. With an increasing movement towards the development of targeted therapies for tumor-specific molecular aberrations, it will be important to determine whether the recurrent tumor bears the same molecular signature as the initial tumor when choosing a therapy.

In a recent study published in *Science*, Dr. Costello and his colleagues sequenced the exomes of initial low-grade and recurrent tumors removed from the same patients. They found that in 43% of the recurrent tumors there was no sign of at least half the mutations found in the original tumor. They also found that tumor recurrences in patients who had been treated with TMZ presented as malignant glioblastoma and showed signs of “hypermutation” – with a 20- to 50-fold increase in the number of mutations.

The hypermutated, TMZ-treated glioblastomas bore a unique genetic signature: 99% of the newly acquired mutations were C>T/G>A transitions, a disproportionate change that is not seen in tumors arising through spontaneous malignant



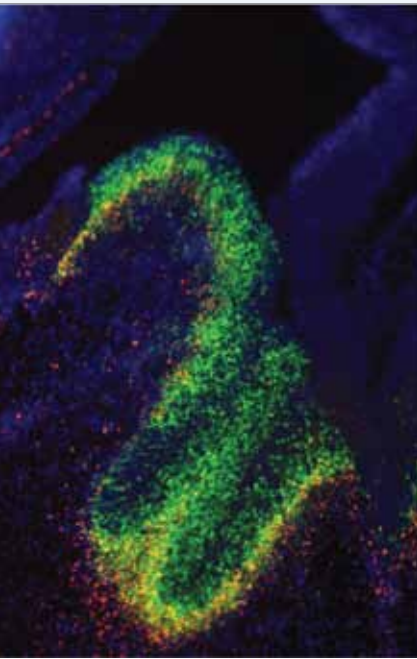
Metabolic MR images from a patient who had an original diagnosis of low-grade astrocytoma that transformed to a grade 4 glioma (glioblastoma) at recurrence. The images show that tissue within the same tumor mass can be low-grade (green) or high-grade (yellow), and these regions may have different types of genetic mutations.

progression. Both spontaneous and TMZ-induced malignant progression occurs through the PI(3)K-AKT-mTOR cell-signaling pathway, but the mechanism for the massively increased number of C>T/G>A transitions is unique to TMZ-treated tumors. This finding reinforces the fact that while chemotherapeutic drugs have tumor-killing properties, some can also behave as mutagenic agents, arguing for more judicious use of them in patients with low-grade tumors.

Building on this work, radiation oncologist Daphne Haas-Kogan MD and neuro-oncologist Jennifer Clarke MD have designed a new clinical trial that will combine TMZ with everolimus – an FDA-approved drug manufactured by Novartis that blocks mTOR. The trial will test the effectiveness of mTOR inhibition in the treatment of newly diagnosed low-grade gliomas and is expected to begin in early 2014. The hope is that patients will receive the tumor-killing benefits of TMZ, while blocking the mutagenic pathway that leads to malignant transformation.

Johnson BE, Mazor T, Hong C, et al. Mutational analysis reveals the origin and therapy-driven evolution of recurrent glioma [published online ahead of print December 12, 2013]. *Science*. doi: 10.1126/science.1239947].

Fluorescent dyes long non-coding RNA molecules and the genes they affect in the developing mouse brain.



The Emerging Role for Long Non-Coding RNA in Tumorigenesis

The human genome has been recently discovered to encode many thousands of long non-coding RNAs (lncRNAs, often pronounced as “link” RNAs), and scientists are now beginning to understand that lncRNAs can have key roles in human disease, including cancer. lncRNAs are loosely defined as molecules longer than 200 nucleotides and do not code for the production of a protein. While the biological function of most lncRNAs is still poorly understood, emerging data have demonstrated the critical role of lncRNAs as “scaffolds” for proteins, and when dysregulated, this lncRNA function can cause disease. For instance, one lncRNA called HOTAIR is present at very high levels in metastatic breast cancer, and when HOTAIR is inhibited, metastasis of these human breast cancer cells is reduced in animal disease models.

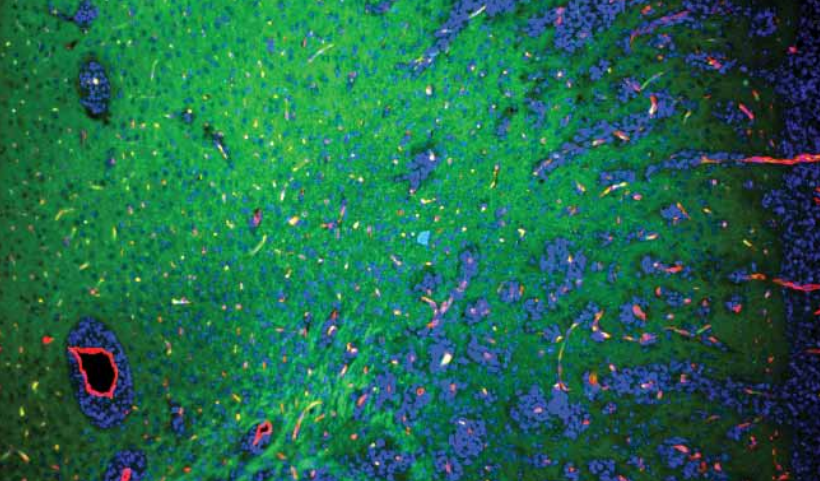
Building from his laboratory’s recent research on lncRNAs in neural stem cells, Daniel

Lim MD, PhD, a principal investigator at the BTRC and the Eli and Edyth Broad Center for Regenerative Medicine, is now investigating patterns of lncRNAs in brain tumor samples. Existing brain tumor microarrays only reveal the patterns in protein-encoding genes. The BTRC is home to one of the largest brain tumor tissue banks in the United States, and by creating a library of lncRNAs from these samples, Dr. Lim hopes to determine whether current classification schemes for brain tumors (such as the Proneural, Neural, Classic, and Mesenchymal groupings) can be further subdivided by the patterns of lncRNA expression. Dr. Lim and his colleagues will also correlate their findings to patients’ treatments, outcomes, and imaging studies, with the hope that characterization of a tumor’s molecular and clinical profile will lead to more precise treatment options. Characterizing the molecular mechanisms by which

lncRNA contributes to tumor formation may also identify new therapeutic targets.

Part of the reason lncRNAs are only now gaining ground as an exciting area of research is that until the advent of high-throughput sequencing technologies, very few lncRNAs were known of or studied in detail. But sophisticated computational analysis tools and next-generation sequencing techniques have unearthed over 10,000 lncRNAs in the last decade. The computational analyses and experiments performed in Dr. Lim’s lab were lead by Alexander Ramos, a student enrolled in the MD/PhD program at UCSF.

Ramos AD, Diaz A, Nellore A, Delgado RN, Park KY, Gonzales-Roybal G, Oldham MC, Song JS, Lim DA. Integration of genome-wide approaches identifies lncRNAs of adult neural stem cells and their progeny in vivo. *Cell Stem Cell* 2013;12(5):616-28.



Mechanisms of Resistance to Anti-Angiogenic Therapy for Brain Tumors

Anti-angiogenic agents, such as bevacizumab, have become widely used in the treatment of glioblastoma. However, while the initial responses to anti-angiogenic therapy are often significant, these agents have had limited durations of response. Many tumors, after responding initially, develop acquired invasive resistance, a rapidly progressive state with a poor prognosis. Mouse models suggest that resistance to anti-angiogenic therapy likely reflects transcriptional or translational changes that are more readily generated than the mutations that typically arise with traditional chemotherapy resistance.

BTRC principal investigator Manish Aghi MD, PhD has recently been awarded an R01 grant from the NIH to investigate the hypothesis that invasive anti-angiogenic therapy resistance is mediated by an interaction between upregulated receptor tyrosine kinase c-Met and β 1 integrin, and that targeting these two factors or their upstream regulators can prevent or overcome therapeutic resistance. The studies will be performed in a unique mouse model of bevacizumab resistance that was developed in the Aghi laboratory at UCSF.

Jahangiri A, Aghi MK, Carbonell WS. Beta1 Integrin: Critical Path to Antiangiogenic Therapy Resistance and Beyond [published online ahead of print December 10, 2013]. *Cancer Res*. doi: 10.1158/0008-5472.CAN-13-1742.

New Statistical Modeling Techniques Improve Predictions of Response to Therapy and Survival for Brain Tumor Patients

When patients are diagnosed with a brain tumor, it is not always possible to predict the course of the disease or what an individual's response to treatment will be. But new applications for an advanced statistical model are helping clinicians to better stratify patients into distinct risk groups.

Biostatistician Annette Molinaro PhD is using the statistical model partDSA to evaluate a wide variety of critical clinical questions at the UCSF Brain Tumor Center. partDSA (Partitioning Deletion/Subtraction/Addition Algorithm) is a recursive partitioning method that can be applied to any clinical question regardless of outcome measure. Whether the variable under study is continuous (e.g., tumor size), binary (e.g., progressed vs. not progressed), or time-dependent (e.g., time to progression), partDSA creates a clinician-friendly decision tree based on various inputs. It also requires fewer partitions to identify groups of patients with similar levels of risk for a given outcome.

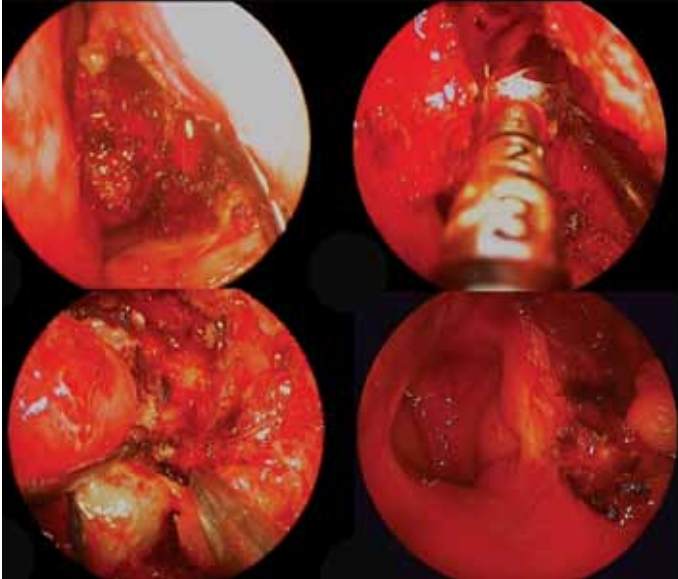
This increased flexibility over standard algorithms, such as CART (Classification

and Regression Tree), has been shown to improve the accuracy and stability of predictions for both uncensored and censored outcomes. This may introduce less bias when analyzing survival results from clinical trials that have lost patients to follow-up.

In an exciting example of how partDSA is being applied to novel brain tumor research, Dr. Molinaro has recently partnered with neuroepidemiologist Margaret Wrensch MPH, PhD to analyze patterns of single nucleotide polymorphisms (SNPs) in patients with brain tumors. Drs. Molinaro and Wrensch hypothesize that the individual variations found in the SNPs of a patient's genome sequence may be able to predict that patient's response to a given drug or their survival time from initial diagnosis. If these ideas can be validated, this study could introduce a powerful new prognostic tool for clinicians and their patients to use in making treatment decisions.

Lostritto K, Strawderman RL, Molinaro AM. A partitioning deletion/substitution/addition algorithm for creating survival risk groups. *Biometrics* 2012;68:1146-56.

Minimally invasive techniques can be used to remove tumors of the skull base through small openings, decreasing postoperative morbidity for patients.



12

Comprehensive Skull Base Surgery Program Offers Expertise in All Treatment Modalities for Tailored Treatment Plans

The Department of Neurological Surgery was recently joined by skull base neurosurgeon Philip Theodosopoulos MD, who is leading the Skull Base Tumor Program by focusing on prospective primary data collection, functional outcome determination, novel treatment schemata, and multimodality treatment. He has extensive expertise in the endoscopic treatment of pituitary adenomas and chordomas and has pioneered new surgical approaches to the skull base.

Until recently, many diseases of the skull base required large, open operations that could result in significant postoperative morbidity and cosmetic disfigurement for patients. With newer procedures and adjuvant therapies focused on

preserving quality of life and reducing morbidity, patients have more options to consider with their physicians.

The evolution of minimally invasive skull base surgery has been an especially important factor in the treatment decision-making process. Endoscopic techniques allow surgeons to remove tumors of the paranasal sinuses and skull base through very small portals. These procedures involve very small or no incisions, resulting in fewer complications, reduced blood loss, and shorter recovery times for patients.

For more information on minimally invasive skull base surgery at UCSF, visit: misb.ucsf.edu.

Socioeconomic Factors Affect Onset of Pituitary Apoplexy

Investigators at the California Center for Pituitary Disorders at UCSF have recently published a report demonstrating that pituitary apoplexy – acute headaches, visual disturbances, and hypopituitarism associated with hemorrhage into a pituitary adenoma – occurs more frequently in uninsured patients, unmarried patients, or patients with limited access to care. Patients with easy access to care are more likely to have tumors identified and treated before developing this devastating condition.

Jahangiri A, Clark AJ, Han SJ, Kunwar S, Blevins LS, Aghi MK. Socioeconomic factors associated with pituitary apoplexy. *J Neurosurg* 2013;119(6):1432-36.

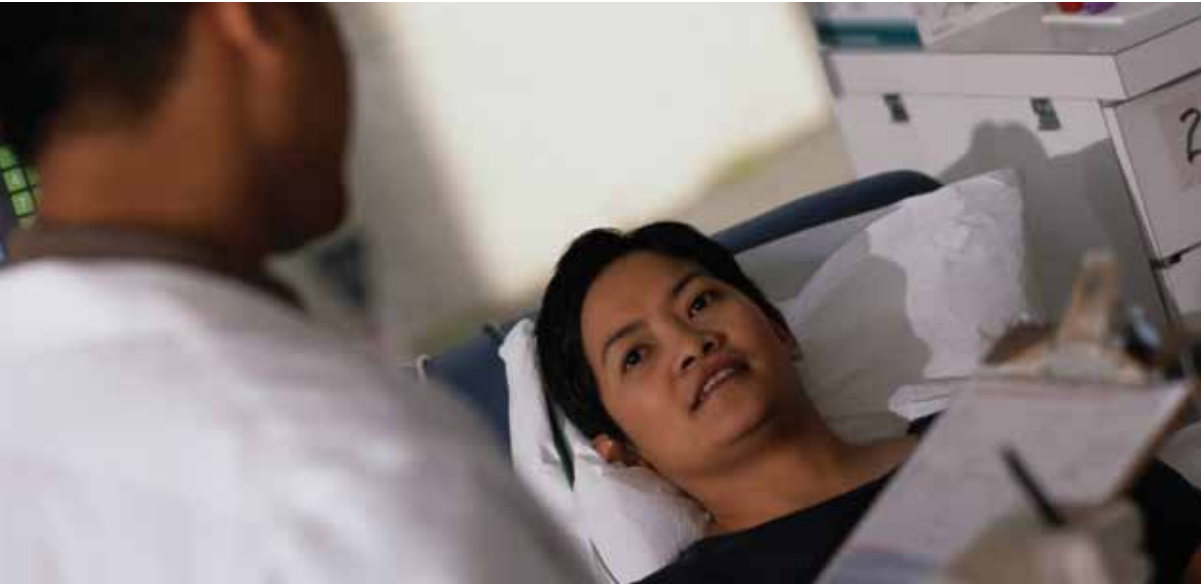Factors Predicting Hyponatremia Following Pituitary Operations

A review of 1045 consecutive pituitary surgeries performed at the California Center for Pituitary Disorders at UCSF showed preoperative hyponatremia to be the only reliable predictor of postoperative hyponatremia. In contrast with results of other, smaller studies, multivariate analysis in this large series showed that factors such as lesion size, lesion location, age, sex, pathology, number of prior surgeries, or surgical approach could not predict whether a patient was more likely to develop hyponatremia following surgery.

Patients with preoperative hyponatremia were best managed with vasopressin receptor antagonists such as conivaptan or tolvaptan. These patients warrant closer follow-up after surgery to promptly identify and treat any persistent hyponatremia.

Jahangiri A, Wagner J, Tran MT, Miller LM, Tom MW, Kunwar S, Blevins L Jr, Aghi MK. Factors predicting postoperative hyponatremia and efficacy of hyponatremia management strategies after more than 1000 pituitary operations. *J Neurosurg* 2013;119(6):1478-83.

Patient Safety and Quality Improvement



In 2013, the Department of Neurological Surgery once again received the Healthgrades Neurosurgery Excellence Award, which recognizes hospitals for superior patient safety outcomes in neurological surgery.

Since 2011, the Department's Patient Safety and Quality Improvement Program has partnered with a multi- and

inter-disciplinary team of providers to provide the safest and highest quality patient care based on the principles of clinical, operational, and academic excellence. The overall aim of the program is to ensure that UCSF is a national leader in neurological surgery quality and patient safety.

Four ongoing key areas of focus for the program include:

- Clinical effectiveness (i.e., reducing mortality, 30-day readmission rates, surgical site infections and other hospital-acquired conditions)
- Clinical efficiency (i.e., improving length of stay and discharge before noon)
- Patient satisfaction
- Resident engagement

Spreading the Importance of Patient Safety in Neurological Surgery


Chair of Neurological Surgery, Mitchel Berger MD, recently completed his term as president of the American Association of Neurological Surgeons (AANS) and led the Annual Scientific Meeting. The theme of the meeting was “Changing Our Culture to Advance Patient Safety.” Multiple leaders in patient safety and quality improvement served as keynote speakers, including Don Berwick, founder of the Institute for Healthcare Improvement and former head of the Centers for Medicare and

Medicaid Services, and Carolyn Clancy, Director of the Agency for Healthcare Research and Quality. In addition, Dr. Berger’s Presidential Address focused on the importance of patient safety and systems improvement, and urged neurosurgeons to embrace systems improvement and patient safety as important pillars of their practice.

Watch the 2013 AANS Presidential Address on neurosurgical patient safety at: <http://bit.ly/16fybr3>



Mitchel S. Berger MD gives the presidential address at the annual meeting of the American Association of Neurological Surgeons (AANS) on the topic of advancing patient safety. Photo courtesy of the AANS.



Residents in the Department of Neurological Surgery participate in the development of Quality Improvement and Patient Safety protocols.

Forming a University of California (UC) Collaborative to Improve and Standardize Neurological Surgery Patient Care

In July 2013, the Patient Safety and Quality Improvement Program was awarded a \$1.2 million grant from the UC Center for Health Quality and Innovation to develop and implement a multi-disciplinary clinical care pathway to improve and standardize neurological surgery patient clinical outcomes and experiences at five UC Medical Center sites: San Francisco, Los Angeles, San Diego, Davis, and Irvine.

The four major aims of this project are to:

- Standardize use of EMMI preadmission by enrolling patients in pre-operative clinics

- Improve MDT communication and safety awareness through standardizing expectations and practices using a Postoperative Debriefing
- Pilot a Postoperative Clinical Care Checklist to reduce postoperative mortality and complications, including CA-UTI, VTE, falls, neurological deficits, and unexpected returns to the operating room
- Understand the patient experience and identify areas for improvement using patient focus groups

This project will be ongoing through June 2016.

Engaging Resident Physician Trainees in Quality Improvement and Patient Safety

A longitudinal Quality Improvement (QI) and Patient Safety curriculum was launched this year for the Department of Neurological Surgery Residency Program. All residents participate in core didactic lectures, perform self-guided online module learning, and obtain hands-on experience in leading QI and patient safety projects through the UCSF Graduate Medical Education QI Incentive Project and a separate QI project of their choice.

Examples of recent and current resident-led GME QI projects include:

- Reducing unnecessary laboratory studies, which resulted in savings of \$1.7 million in billable charges to health care payers
Han SJ, Saigal R, Rolston J, Cheng JS, Lau CY, Mistry RI, McDermott MW, Berger MS. Targeted reduction in neurosurgical laboratory utilization: resident-led effort at a single academic institution. **J Neurosurg** 2014;120(1):173-77.
- Improving timeliness and accuracy of brief post-operative notes in the electronic medical record and improving timely, direct communication with the accepting post-operative nurse
- Standardizing a procedural timeout and safety checklist prior to the placement of external ventricular drains

For further information on the Neurological Surgery Patient Safety and Quality Improvement Program, contact Catherine Lau MD at clau@medicine.ucsf.edu.

Faculty

Neurotrauma

San Francisco
General Hospital

Sanjay Dhall MD

Geoffrey Manley MD,
PhD

Michael Huang MD

Phiroz Tarapore MD

BASIC Laboratories

Michael Beattie PhD
central nervous
system repair

Jacqueline Bresnahan
PhD
central nervous
system repair

Adam Ferguson PhD
bioinformatics

Jialing Liu PhD
neurogenesis and
functional recovery

16 Geoffrey Manley MD,
PhD
basic, translational, and
clinical traumatic brain
injury research

Linda Noble-Haeusslein
PhD
neuroinflammation in
traumatic brain and
spinal cord injury

S. Scott Panter PhD
cellular injury following
stroke and hemoglobin-
based neurological injury

Susanna Rosi PhD
chronic neuro-
inflammation;
learning and memory

Brain & Spinal Injury Center



Chief of Neurotrauma, Geoffrey Manley MD, PhD, confers with a veteran trauma team at San Francisco General Hospital

National Institutes of Health Grants \$18.8 Million Over Five Years to Support Worldwide Research on Concussion and Traumatic Brain Injury

A new NIH award for traumatic brain injury research, part of one of the largest international research collaborations ever coordinated by funding agencies, will be administered through UCSF.

The award supports a team of U.S. researchers at more than 20 institutions throughout the country who are participating in the International Traumatic Brain Injury (InTBIR) Initiative, a collaborative effort of the European Commission, the Canadian Institutes of Health Research (CIHR), the National Institutes of Health (NIH), and the U.S. Department of Defense (DOD). Geoffrey Manley, MD, PhD, chief of neurosurgery at San Francisco General Hospital and a principal investigator

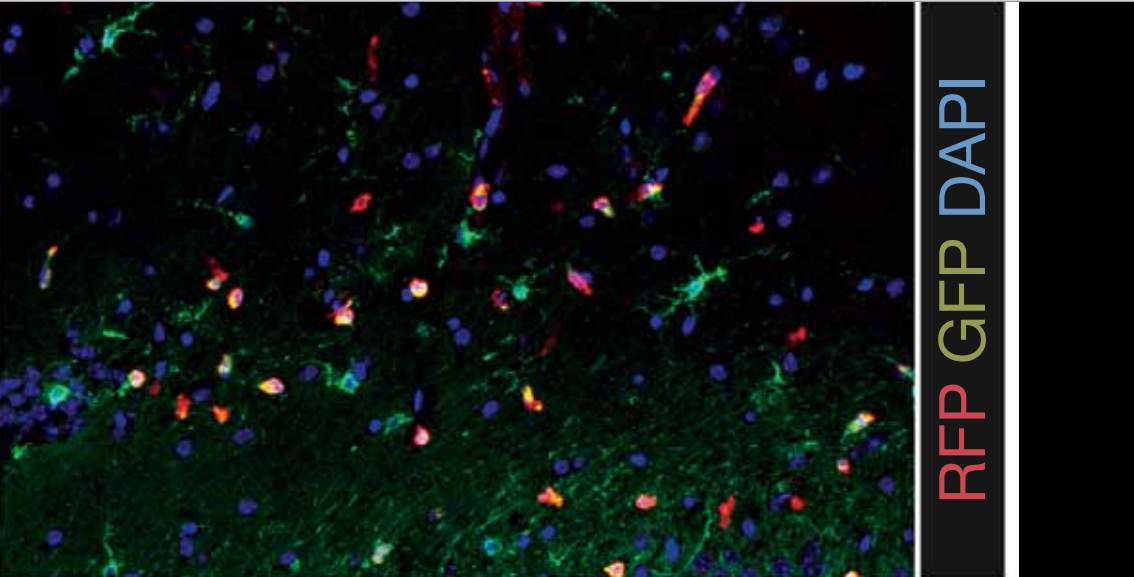
for the grant, will serve as the U.S. research team's primary liaison to the NIH.

In the work funded by the NIH grant – which also is supported by contributions from the private sector and from the nonprofit One Mind for Research – the researchers aim to refine and improve diagnosis and treatment of TBI, which often has insidious health effects, but which frequently is undiagnosed, misdiagnosed, inadequately understood and undertreated.

Since 2009, Dr. Manley and Pratik Mukherjee, MD, PhD, a professor of radiology and biomedical imaging at UCSF, have helped lay the groundwork for the continuing TBI research by leading the NIH-funded

TRACK-TBI project, through which they and their research collaborators have demonstrated the value of gathering common data across research sites.

The new NIH award funds a continuation and expansion of TRACK-TBI. Among the goals is the creation of a widely accessible, comprehensive “TBI information commons” to integrate clinical, imaging, proteomic, genomic and outcome biomarkers from subjects across the age and injury spectra. Another goal is to establish the value of biomarkers that will improve classification of TBI and better optimize selection and assignment of patients for clinical trials.



Activated microglia (green) and infiltrating macrophages (red) can be seen in the brain after traumatic brain injury in rodents.

The researchers also aim to evaluate measures to assess patient outcomes across all phases of recovery and at all levels of TBI severity, to determine which tests, treatments, and services are effective and appropriate – depending on the nature of TBI in particular patients.

TRACK-TBI clinical enrollment sites throughout the United States will enroll 3,000 patients across the spectrum of mild to severe brain injuries. Clinical, imaging, proteomic, genomic and clinical outcome databases will be linked into a shared platform that will promote a model for collaboration among scientists within InTBIR and elsewhere.

Targeting Peripheral Macrophages in Traumatic Brain Injury

It has been well documented that traumatic brain injury (TBI) induces a cascade of cellular responses, including activation of the brain's innate immune effectors, microglia. Activation of these cells can persist for extended periods, even years, following the initial mechanical insult.

Following brain injury microglia cells resemble, both morphologically and phenotypically, peripheral blood-derived macrophages. Therefore, it has been difficult to fully delineate the role of peripherally derived (blood-born) CCR2+ macrophages in the pathogenesis and neurodegenerative sequelae following brain injury.

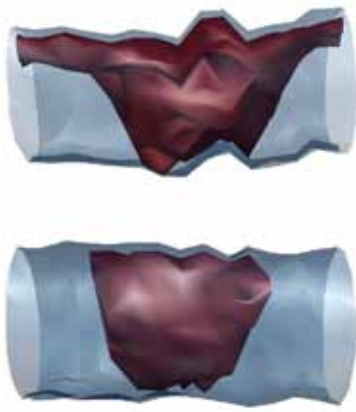
Recent studies from the UCSF Brain and Spinal Injury Center (BASIC) have shed light on the temporal kinetics and inflammatory profile of peripherally derived macrophages in the brain following injury.

To unambiguously discriminate resident microglia and investigate macrophage trafficking in vivo, BASIC researchers utilized a unique reporter mouse (CCR2RFP/+CX3CR1GFP/+) to accurately delineate the resident (CX3CR1+) versus peripheral (CCR2+) innate immune response in the brain following TBI. This genotype allows for characterization of central (CX3CR1+) versus peripheral (CCR2+) macrophage populations by

flow cytometry. Specifically, data suggest that peripheral CCR2+ macrophage infiltration is relegated to a short time frame following injury. However, the neuroinflammatory response before, during, and after infiltration is phenotypically distinct.

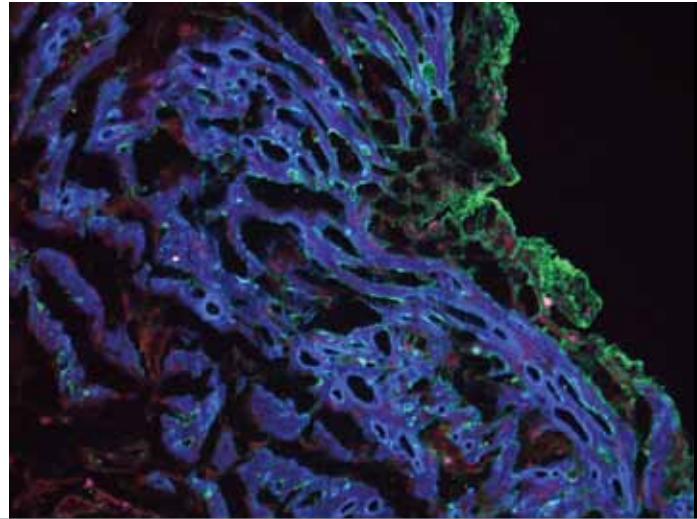
In an extension of these findings, a novel CCR2 antagonist (currently in Phase I trials) has shown promising effects in the reduction of TBI-induced peripheral macrophage infiltration. Furthermore, blocking the infiltration of these cells into the injured central nervous system diminishes pro-inflammatory response as well as reduces production of neurotoxic reactive oxygen species mediators. Most importantly, the novel CCR2 antagonist able to prevent peripheral cell accumulation following TBI has been shown effective in abrogating TBI-induced cognitive dysfunction.

This work was performed by Dr. Josh Morganti PhD in the laboratory of Principal Investigator Susanna Rosi PhD and was funded by the Alzheimer's Association and the National Institute of Health.



3D reconstructions of a representative DMSO (vehicle)-treated mouse (top figure) and a GM6001 (drug)-treated mouse (bottom figure). Serial coronal sections of mouse spinal cord were analyzed using the Cavalieri method in Stereo Investigator from which a 3D reconstruction was generated, showing that the drug treatment resulted in a smaller lesion size than vehicle alone. Red color denotes lesion after a moderate-severe spinal cord injury. Translucent blue color represents spared spinal cord tissue.

Urinary bladder tissue of a spinal cord-injured mouse 6 weeks after injury, with urothelium at right (magnification is 20X). Blue: alpha-actin; green: collagen I; red: collagen III. Collagen III is interspersed in the muscle layer after injury, suggesting that scarring has occurred.



Drug to Protect Against Secondary Damage to Spinal Cord Also Improves Bladder Function Following Moderately Severe Spinal Cord Injury

18 In 2002, principal investigator Linda Noble-Haesslein PhD and her colleagues discovered that mice with moderate spinal cord injuries could significantly improve their functional recovery if they were given the drug GM6001 three hours after injury. GM6001 is an inhibitor of matrix metalloproteinase-9 (MMP-9), which facilitates leukocyte infiltration past the blood-spinal cord barrier during the acute phase of spinal cord injury. The inflammatory cascade that follows worsens the severity of the injury and has poor implications for recovery. Blocking MMP-9 reduces abnormal vascular permeability and secondary damage caused by acute inflammation.

Now several members of Dr. Noble's lab – Thomas Fandel, Alpa Trivedi, Kayleen Gimlin,

Haoquian Zhang, and Aida Martinez – have expanded this work to determine if GM6001 could have a longer therapeutic window and if it could be as effective with more severe injuries. In a randomized and blinded study, mice were given GM6001 eight hours after sustaining either a moderately severe or severe spinal cord injury. The drug significantly improved neurological function in the moderately severe group, but not in those with severe injury. These findings, together with earlier studies by this group, define a substantial population of moderate to moderately severe spinal cord injured patients that might benefit from this drug. Moreover, increasing the therapeutic window of the drug by five hours has large implications for its use, as there may be delays in initiation of


treatment due to the location of the patient relative to the nearest medical facility or necessary medical diagnostic procedures that must proceed any decision to treat.

The investigators also examined the drug's effect on bladder function, which is a major quality-of-life issue for patients with spinal cord injury. By using awake cystometry, they measured the level of dyssynergia – the inability to maintain normal bladder contractions – happening in the mice after injury and after receiving the drug. As with neurological function, bladder function was significantly improved in the mice with moderately severe injuries. Bladder function is controlled by white matter fiber tracts descending from the brainstem that interact with local circuitry in the spinal cord. The researchers

theorize that partial protection of these tracts by MMP-9 blockade facilitates the much needed descending input to this local circuitry. Another consequence of spinal cord injury is a thinning of the bladder wall that results from loss of muscle and scarring. But after administration of GM6001, these abnormal changes are reduced, suggesting that the drug also affects how the bladder wall remodels itself after injury.

This research was funded by a grant from the U.S. Department of Defense.

Fandel T, Trivedi A, Gimlin K, Zhang H, Martinez A, Noble-Haesslein L. Acute treatment with the matrix metalloproteinase inhibitor GM6001 improves long-term locomotor and bladder function in a murine model of spinal cord injury. Presented at the Annual Meeting of the Society for Neuroscience, San Diego, CA, November 9-13, 2013.



Creating a Pre-clinical Model of Social Deficits Following Traumatic Injury to the Developing Brain

Postdoctoral fellow Bridget Semple PhD and staff research associate Sandra Canchola BA have been leading an effort to develop robust social assays of mouse behavior in the Noble-Haeusslein laboratory. Clinical studies have shown that children who experience traumatic brain injuries (TBI) while their brains are still developing are at risk not only for cognitive problems, but also abnormal social and communication problems. Social deficits are rarely taken into account when investigating new therapeutics for TBI, and there are currently no preclinical pediatric models that address this issue despite the devastating consequences of these deficits on quality of life.

Using a battery of tests used to study social deficits

associated with autism, the investigators compared the results of mice that sustained brain injuries at postnatal day 20 to those of mice undergoing sham surgery. The mice with injured brains showed social deficits that were not apparent in sham surgery counterparts; but, interestingly, these deficits were not apparent until the mice became adults. As juveniles, no social deficits were apparent in either cohort, but when the skills became needed as the mice matured, the injured mice clearly lacked the ability to interact as successfully. The tests included analyses of established behaviors that address social novelty, social dominance, and memory of previous social interactions. The Noble laboratory has also more recently been exploring the use of an ultrasonic vocalization

paradigm to study how mice communicate with each other under different social contexts and the extent to which this communication may be altered after brain injury.

These assays could enhance future evaluation of TBI therapies by providing a way to determine if an intervention could improve social function as well as more traditional measures of neurological and cognitive function.

Semple BD, Canchola SA, Noble-Haeusslein LJ. Deficits in social behavior emerge during development after pediatric traumatic brain injury in mice. *J Neurotrauma* 2012;29(17): 2672-83.

Adahman Z, Lee HY, Semple B, Hollingsworth C, Kwakye A, Jan LY, Jan YN, Noble-Haeusslein L, Schenk AK. Using adult mouse ultrasonic vocalizations as an assay of social communication. Presented at the Annual Meeting of the Society for Neuroscience, San Diego, CA, November 13, 2013.

Faculty

Vascular Neurosurgery

Michael Lawton MD

Michael Huang MD

Michael McDermott MD (Gamma Knife radiosurgery)

Cerebrovascular Research Laboratories

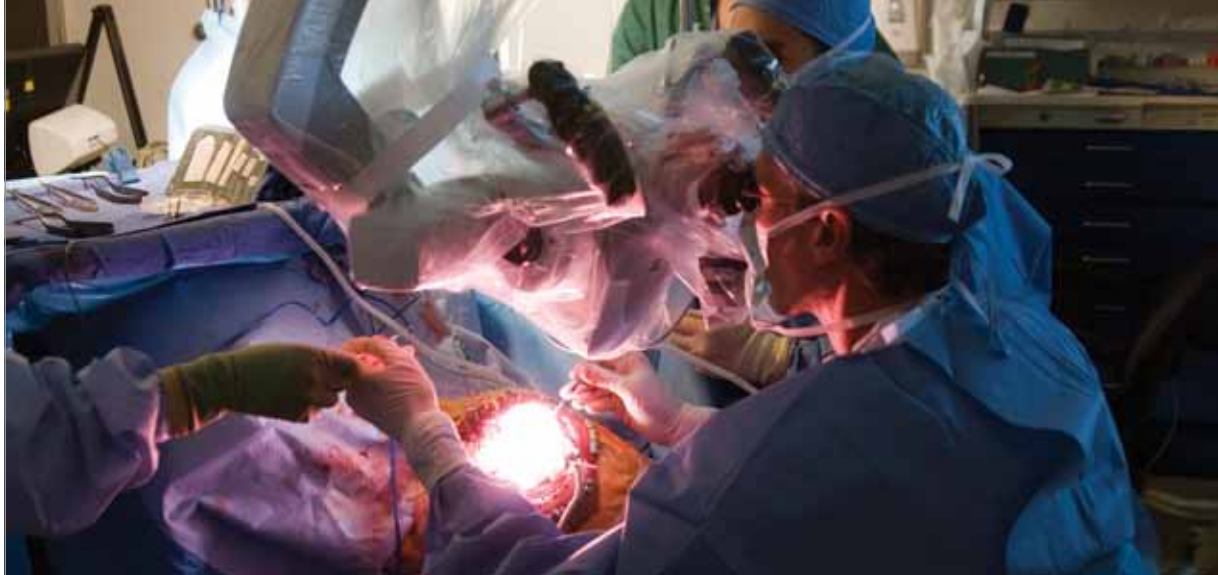Arnau Benet MD
Surgical anatomy; novel surgical approaches

Michael Lawton MD
Pathophysiology of arteriovenous malformations; hemodynamics of aneurysms; radiation-induced arteriopathy

Jialing Liu PhD
Neurogenesis and functional recovery after stroke

S. Scott Panter PhD
Animal models of stroke and traumatic brain injury

Vascular Neurosurgery



Chief of Vascular Neurosurgery, Michael Lawton MD

The Vascular Manifesto

UCSF's Chief of Vascular Neurosurgery, Michael Lawton MD, was chosen to give the distinguished Hunt-Wilson Lecture at the 2013 Scientific Meeting of the American Association of Neurological Surgeons. Drawing on over 16 years of experience specializing in cerebrovascular neurosurgery, Dr. Lawton delivered his "Vascular Manifesto," highlighting the seven areas vascular neurosurgeons should aim to excel in.

With thousands of procedures for aneurysms, cavernous malformations, arteriovenous malformations, and ischemic disorders under his belt, here are the hard-won lessons key to Dr. Lawton's success:

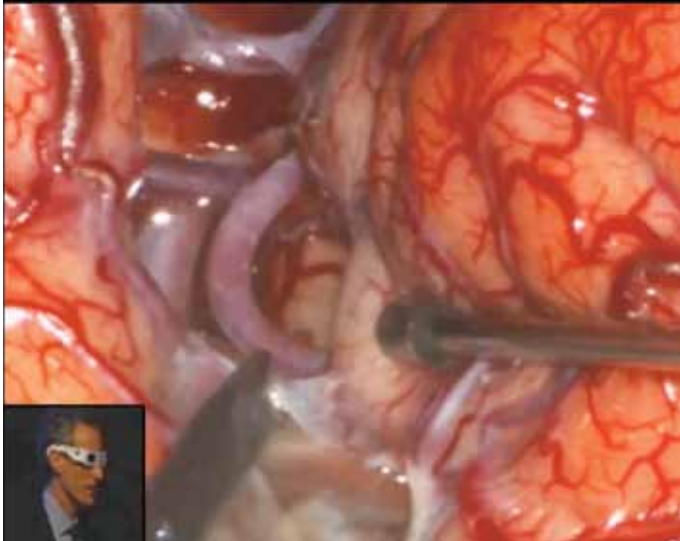
- 1) Stay Out of the Brain: "Almost any target in the brain can be reached by dissecting through subarachnoid spaces and preserving the brain's integrity"
- 2) Manual Dexterity: "Dexterity is our most important skill as neurosurgeons and we develop it through practice and hard work and perfectionism"
- 3) Case Volume & Experience: "Volume is the secret to success because it advances us through our learning curves, develops our technique, and turns into experience over time"
- 4) Daring: "Vascular neurosurgeons must be the ones to do what no one else wants to do"
- 5) Surgical Strategy: "Neurosurgeons must know their pathology, think about their techniques, and develop strategies that guide them through the operation step by step"
- 6) Precision: "Open surgery should be as precise as possible, opening only what is necessary and adapting to changing skills and environments"
- 7) Performance: "Neurosurgery is more than just surgery, and requires us to perform at our highest level in the patient's interest, choosing the best way rather than the easy way"

Bringing the Operating Room to You: Online Videos of Cerebrovascular Procedures Support Learning

Online video publications in neurosurgery are becoming increasingly valuable educational tools. They are accessible at any time, can help residents and fellows to learn surgical techniques from different instructors, and allow established surgeons to keep up with new technologies and approaches. Originally used primarily as a supplement to text, videos are now being presented as stand-alone publications indexed in MEDLINE.

Visual presentation can be especially useful for technically demanding cerebrovascular procedures that can be difficult to describe with a narrative alone. UCSF neurosurgeons have been at the forefront of this trend, frequently videotaping and streaming surgical cases while displaying them on 3-D screens in the operating room for visitors.

Michael Lawton MD serves as co-editor of the 3-D video section produced by *Neurosurgery* – a resource that emphasizes high-quality content by leaders in various neurosurgical subspecialties. 3-D forums at scientific meetings are also becoming increasingly common and provide a new way for colleagues to interact and learn from one another.



Michael Lawton MD (lower left-hand corner) narrates a 3-D video showing bypass techniques for a giant MCA aneurysm. Image printed with permission from: Lawton MT. My Pearls of Technique: A Review of Challenging Cases. Neurosurgical Atlas Web site. <http://www.neurosurgicalatlas.com/video-conference-archive/my-pearls-of-technique-a-review-of-challenging-cases2>. Accessed November 22, 2013. © Aaron Cohen-Gadol M.D.

Recent Cerebrovascular Video Publications from UCSF

Abla AA, Englot D, Lawton MT. Retrosigmoid craniotomy for clipping of two vertebrobasilar junction aneurysms. *Neurosurg Focus* 2014;36(1 Suppl):1.

Abla AA, Clark A, Lawton MT. Resection of pontine cavernous malformation through the pontomedullary sulcus. *Neurosurg Focus* 2014;36(1 Suppl):1.

Rodriguez-Hernandez A, Lawton MT. Microsurgical technique for PICA-PICA in situ bypass: 3D operative video. *Neurosurgery*. 2013 Jul 9.

Rodriguez-Hernandez A, Lawton MT. Contralateral transcallosal approach to basal ganglia cavernous malformation: 3-Dimensional operative video. *Neurosurgery* 2013;72(2 Suppl Operative):ons182.

Rodriguez-Hernandez A, Lawton MT. Management of a recurrent coiled giant posterior cerebral artery aneurysm with trapping and thrombectomy: 3-D operative video. *Neurosurgery* 2012;71(2 Suppl Operative):ons191.

Rodriguez-Hernandez A, Gabarros A, Lawton MT. Contralateral clipping of middle cerebral artery aneurysms: Rationale, indications, and surgical technique. *Neurosurgery* 2012;71(1 Suppl Operative):116-23.

Rodriguez-Hernandez A, Lawton MT. End-to-end reanastomosis technique for fusiform aneurysms: 3-D operative video. *Neurosurgery*. 2013 Aug 5.

Conditional Ablation of Neuroprogenitor Cells Impedes Recovery of Poststroke Cognitive Function

A study done in the laboratory of Principal Investigator Jialing Liu PhD has shown that impairment of the brain's stem cells leads to worse memory after experimental stroke. Dr. Liu and her colleagues subjected two groups of mice – a line of transgenic mice that are unable to produce new neurons when exposed to the drug ganciclovir and wild-type control mice – to experimental stroke that produced mild cognitive impairment. Half of the mice in each group were exposed to saline, while the other half were given ganciclovir. The results showed that following stroke, mice lacking new neurons performed worse

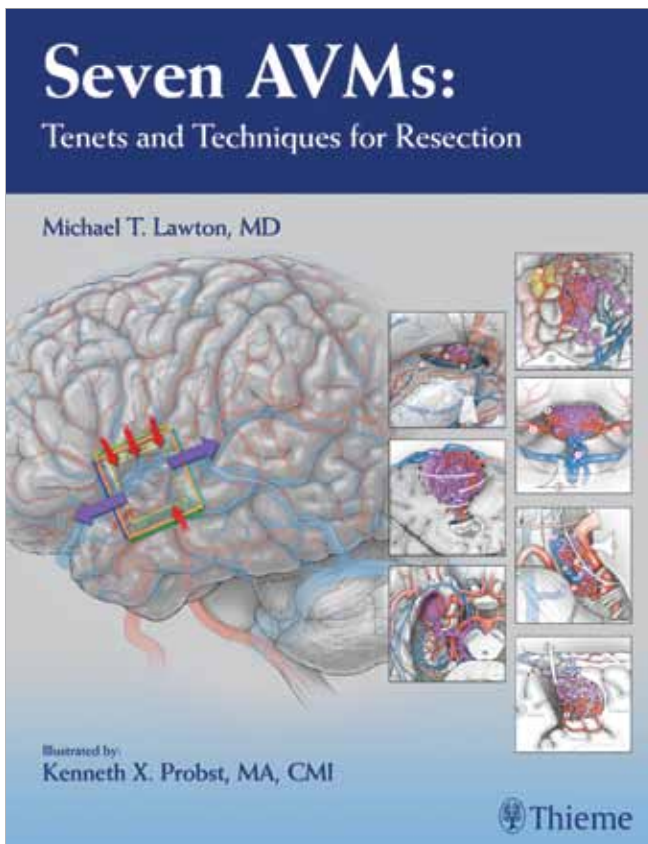
in a cognitive test involving spatial learning and memory. However, the performance of wild-type mice was not affected by the drug, nor was their ability to produce new neurons. This finding affirms that the affected learning and memory capacity is directly related to the ability to generate new nerve cells, rather than potential drug toxicity.

The investigators also found that the inability of mice to produce new neurons after stroke impaired connectivity in the hippocampal circuitry, the function of which is crucial in the cognitive test used in the study. Their findings suggest that continuous neurogenesis

after stroke is necessary for learning and is required to maintain a functional network involved in hippocampal-dependent memory. The study also raises the possibility that stem cell therapy or treatment that enhances endogenous stem cell regeneration could be harnessed to improve the ability to recover from stroke and perhaps reduce dementia in stroke victims.

Sun C, Sun H, Wu S, Lee CC, Akamatsu Y, Wang RK, Kernie SG, Liu J. Conditional ablation of neuroprogenitor cells in adult mice impedes recovery of poststroke cognitive function and reduces synaptic connectivity in the perforant pathway. *J Neurosci* 2013;33(44):17314-25.

22



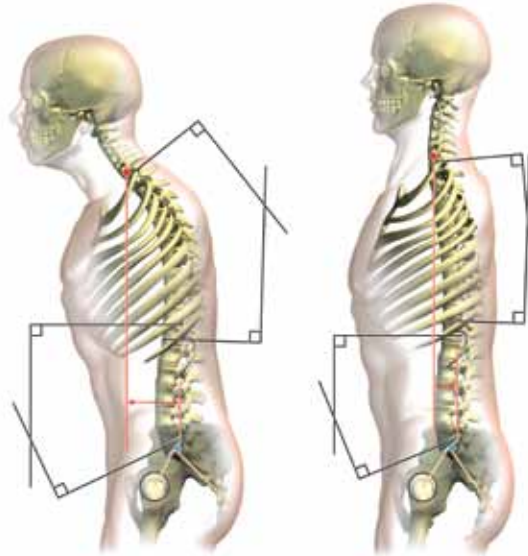
Sneak Peek: Seven AVMs

In a follow-up to the highly regarded textbook “Seven Aneurysms: Tenets and Techniques for Clipping,” Michael Lawton MD presents a new reference to guide readers through the world of arteriovenous malformations. The textbook outlines a system for defining subtypes of AVMs and surgical strategies for tackling them in eight steps. To be published in April, 2014 by Thieme, the highly anticipated book again features pages of original illustrations by award-winning medical illustrator Kenneth Xavier Probst.

Neurospinal Disorders

Faculty

Christopher Ames MD
Dean Chou MD
Sanjay Dhall MD
Praveen Mummaneni MD
Philip Weinstein MD



UCSF Spine Surgeon Wins Prestigious Awards for Clinical Research

UCSF is one of the largest participating sites for the Scolio Risk 1 Trial - the first prospective, international trial to specifically study the rates of neurological injury following severe deformity correction and complex osteotomy. Early results were described in the presentation "Propsective, Multicenter Assessment of Acute Neurological Complications Following Complex Adult Spine Deformity Surgery: The Scolio Risk 1 Trial," which earned UCSF Study PI Christopher P. Ames MD and the rest of the Scolio Risk 1 Trial team the Russell S. Hibbs Clinical Award for the best clinical presentation at the 2013 Scoliosis Research Society Annual Meeting.

Dr. Ames was also honored with the Whitecloud Award for best clinical paper at the 20th

Annual Meeting on Advanced Spine Techniques. The study, for which he served as PI, concluded that treatment of flatback syndrome results in the same level of improvement seen in adults treated for major global sagittal deformity and will likely change surgical treatment strategies on patients with flatback syndrome.

Singh M, Smith JS, Klineberg E, Shaffrey CI, Lafage V, Schwab F, Protosaltis T, Mundis GM, Hostin R, Deviren V, Scheer JK, Hart RA, Burton DC, Bess S, Ames CP; International Spine Study Group. Surgical Treatment of the Pathological Loss of Lumbar Lordosis (Flatback) in the setting of normal sagittal vertebral axis (SVA) achieves similar clinical improvement as surgical management for elevated SVA. Presented at the 20th Annual Meeting on Advanced Spine Techniques; Vancouver, Canada; July 11, 2013.

Patient Outcomes After Spine Surgery Create First Benchmarks from the National Neurosurgery Quality and Outcomes Database

In 2013 UCSF became one of 28 sites to begin entering data on patient outcomes into the National Neurosurgery Quality and Outcomes Database (N²QOD). The goal of the project, sponsored by the American Association of Neurological Surgeons/NeuroPoint Alliance, is to gather real-time, nationwide data on neurosurgical patient outcomes that can be used to provide measures of safety, quality, and cost-effectiveness of various neurosurgical procedures.

The effort to report data at UCSF is being led by neurospine surgeon and N²QOD Scientific Committee member Praveen Mummaneni MD. The first module launched in 2013 gathered data on lumbar disc procedures, and was followed by a module for cervical spine disorders. Initial data collected across 13 centers was published in *Journal of Neurosurgery Spine*, demonstrating the efficacy of lumbar discectomy and single-level fusion for spondylolisthesis.

There are now 30 participating clinical sites nationwide. The next module to be launched will gather data on cerebrovascular procedures in 2014.

Ghogawala Z, Shaffrey CI, Asher AL, Heary RF, Logvinenko T, Malhotra NR, Dante SJ, Hurlbert RJ, Douglas AF, Magge SN, Mummaneni PV, Cheng JS, Smith JS, Kaiser MG, Abbed KM, Sciubba DM, Resnick DK. The efficacy of lumbar discectomy and single-level fusion for spondylolisthesis: results from the NeuroPoint-SD registry. *J Neurosurg Spine* 2013;19(5):555-63.

The Benefits of Intraoperative Neuromonitoring with Motor Evoked Potentials in the Cervical Spine

Although intraoperative neurophysiological monitoring (IONM) techniques are widely used during surgery for spinal deformity and spinal tumors, the benefits of these techniques during decompressive operations in the cervical spine are not as well established.

IONM with motor evoked potentials (MEP) is a highly sensitive measure of nerve integrity and may be able to detect neurological injury faster than IONM with somatosensory evoked potentials. However, in addition to injury caused by retraction of the spinal cord, IONM MEP alerts can also be triggered by

equipment failures or by a decrease in blood pressure perfusion that happens as a result of an increase in anesthesia. There have also been incidents in which postoperative neurological deficits arise despite normal IONM MEP readings.

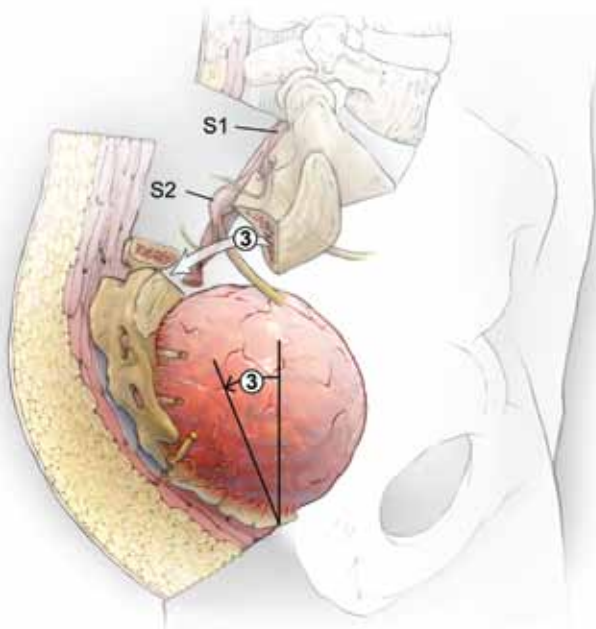
In a recent study, a group of investigators from the UCSF Neurospinal Disorders Program reviewed 140 consecutive decompressive procedures for cervical or cervicothoracic myelopathy that employed IONM MEP. They found that MEPs had high specificity (92%) and sensitivity (75%) for detecting injury in cervical or cervicothoracic myelopathy cases, and sensitivity is even

higher for patients without vascular risk factors, patients older than 65 years, and patients with preoperative neurological deficits.

Despite the higher cost and specialization needed to correctly interpret results, these findings indicate that IONM MEP is helpful in predicting and preventing neurological injury, especially during procedures to treat neck stenosis or spinal cord compression.

Clark AJ, Ziewacz JE, Safaee M, Lau D, Lyon R, Chou D, Weinstein PR, Ames CP, Clark JP 3rd, Mummaneni PV. Intraoperative neuromonitoring with MEPs and prediction of postoperative neurological deficits in patients undergoing surgery for cervical and cervicothoracic myelopathy. *Neurosurg Focus* 2013;35(1):E7.

24



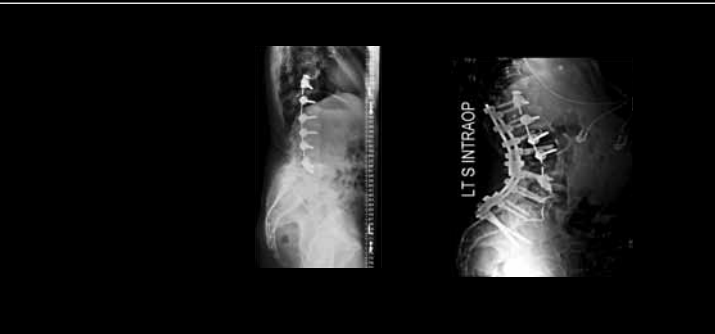
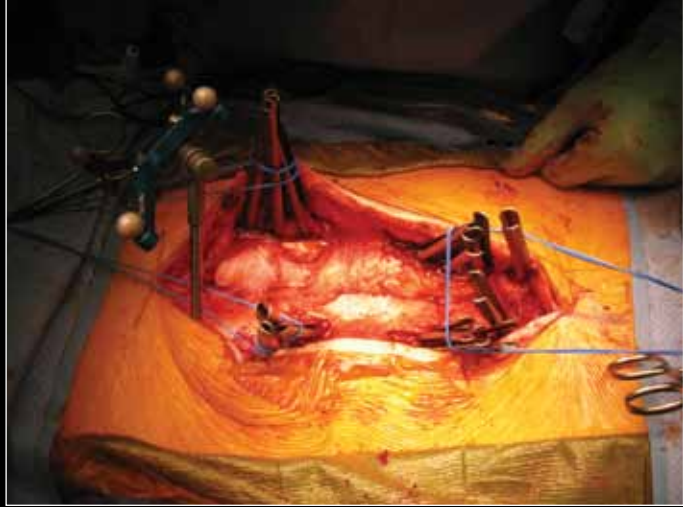
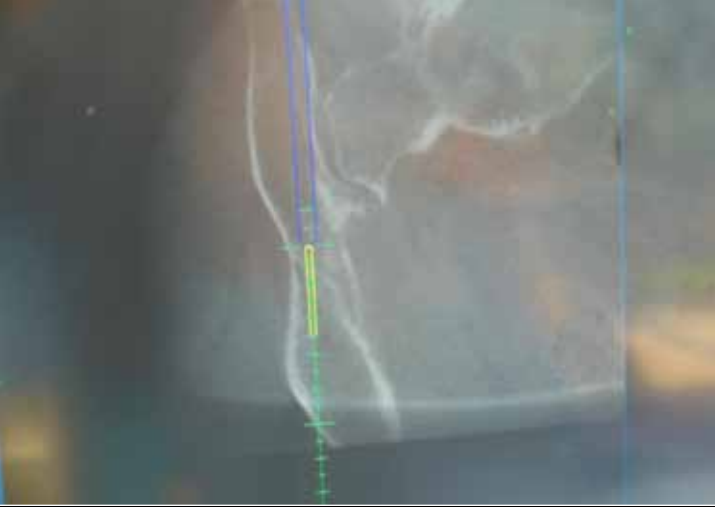A new technique for sacral chordoma removal preserves the S2 nerve rootlets, increasing the chances for normal bowel and bladder function after surgery.

New Surgical Technique Can Greatly Enhance Quality of Life for Patients with Sacral Tumors

The most common morbidity following sacral chordoma removal is bowel and bladder dysfunction. Neurosurgeons typically try to remove the tumor as a whole (in what is known as an 'en bloc' resection) to prevent seeding of residual tumor cells and recurrence. Sacral chordomas can recur as soon as 8 months after surgery if any piece of the tumor is left behind. During en bloc resection, the proximal-most nerves (S2 nerve rootlets) that control bowel and bladder functions are often sacrificed to achieve a wide margin around the tumor. But with a new technique, neurosurgeons may be able to more frequently preserve these nerves. By removing the bone that normally encases the nerve and then gently retracting the nerve up and away from the tumor, the tumor can be removed without severing the nerve. Leaving these nerves intact can help to preserve bowel and bladder function, greatly enhancing quality of life.

The new technique was developed by Dean Chou MD together with UCSF neurosurgery resident Rajiv Saigal MD, PhD, UCSF urologist Donna Deng MD, and their colleague and former UCSF resident Daniel Lu MD, PhD, assistant professor of neurosurgery and orthopedic surgery at the University of California, Los Angeles. Details on the technique will appear in *Journal of Neurosurgery*, along with an instructional video.

Saigal R, Lu DC, Deng DY, Chou D. Conversion of high to mid sacral amputation via S2 nerve preservation during partial S2 sacrectomy for chordoma. *J Neurosurg*, In Press.



Intraoperative use of navigation allows minimally invasive pedicle subtraction osteotomy to be performed safely and with increased accuracy, yet with much less muscle dissection than with an open procedure.

Although the skin incision is the same as in an open case, the tissue manipulation underneath is far less. The paraspinal muscles are mainly

left attached to the spine instead of being stripped off and dissected as in conventional open surgery.

Preoperative and postoperative x-ray images demonstrate the restoration of lordosis and correction of deformity that can be achieved with a minimally invasive pedicle subtraction osteotomy.

Minimally Invasive Procedure for Pedicle Subtraction Osteotomy

The Neurospinal Disorders group at UCSF is continually at the forefront of minimally invasive surgical techniques for spinal deformity. For patients who need further surgery after previously having undergone fusion, minimally invasive pedicle subtraction osteotomy (MIPSO) can

provide stability with less muscle dissection and blood loss than occurs with standard open procedures.

Pedicle subtraction osteotomy is not typically done through a minimally invasive opening and is a new option for patients with

failed fusion – there has only been one previously reported case of MIPSO. At UCSF, the procedure, pioneered by Dean Chou MD, is performed using intraoperative neuronavigation and real-time imaging to improve safety and accuracy.

New Algorithm to Determine When Minimally Invasive Surgery Can Be Used For Deformity

Minimally invasive surgery offers many potential advantages over open surgery for spinal disorders, including less blood loss, shorter recovery times, and less manipulation of the spinal cord. Technological improvements made over the last five years have expanded its use for treating complex deformity, such as vertebral column resection for severe rigid deformity. However, not all types of deformity can be sufficiently treated with minimally invasive techniques and some patients undergoing these procedures receive inadequate corrections.

Spine neurosurgeons at UCSF have recently developed an algorithm to help physicians determine when minimally invasive deformity is appropriate for a case of spinal deformity. The algorithm is currently being validated in a trial by the International Spine Study Group.

Faculty

Movement Disorders Surgery

Philip Starr MD, PhD
Edward Chang MD
Paul Larson MD
Daniel Lim MD, PhD

Movement Disorders Research Laboratories

Krystof Bankiewicz MD, PhD
Gene therapy and drug-delivery strategies
Paul Larson MD
Neurotransplantation strategies for Parkinson's disease
Philip Starr MD, PhD
Basal ganglia physiology in movement disorders; neurogenesis and functional recovery

Movement Disorders



Directors of the Surgical Movement Disorders Program Jill Ostrem MD and Philip Starr MD, PhD (left) with Bachmann-Strauss Foundation president Bonnie Strauss and Chairman of Neurological Surgery Mitchel Berger MD.

UCSF Named a Bachmann-Strauss Center of Excellence for Dystonia and Parkinson's Disease

The Bachmann-Strauss Dystonia and Parkinson Foundation has granted a \$400,000 Center of Excellence award to help UCSF's Surgical Movement Disorders Program continue its innovative work in patient care and technology development.

The Foundation's president and founder Bonnie Strauss presented the award in a ceremony on November 5, 2013. In attendance were patients with widely varying journeys who shared their stories of success and hope for the future. UCSF joins Beth Israel (New York), the University of Alabama, and the University of Florida as the fourth Bachmann-Strauss Center of Excellence in the nation.

Ten years ago, surgery for movement disorders at UCSF was as a collaborative effort

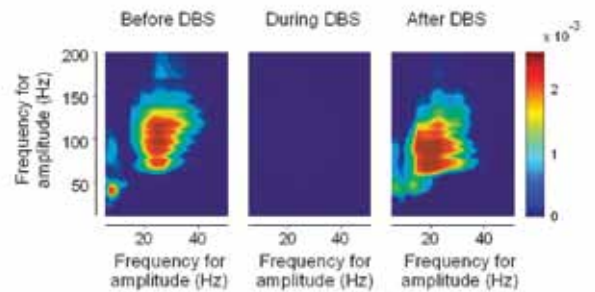
among neurosurgeons Philip Starr MD, PhD and Paul Larson MD, neurologists Jill Ostrem MD and William Marks MD, and clinical nurse specialist Monica Volz RN. Their goal was to better identify patients who could benefit from deep brain stimulation surgery, which was newly approved by the FDA for essential tremor and Parkinson's disease, and offer that option when possible. Prior to 1997, surgical treatment for movement disorders was primarily an ablative procedure that destroyed normal brain tissue and could produce significant side effects. That small group of dedicated clinicians has since grown into a comprehensive program of 27 members that is among the highest volume surgical treatment centers in the nation.

The Surgical Movement Disorders Program has become a leader in basic science and clinical research. There are currently 23 ongoing research protocols, including several aimed at identifying genetic variance among patients with movement disorders to improve prognosis, predict response to treatment, and identify new therapeutic targets.

The program is also widely known for the technical innovations in DBS surgery that have emerged over the last several years. In 2008, Drs. Starr and Larson, together with their Neuroradiology colleague Alastair Martin PhD and medical device company MRI Interventions, developed an MRI-compatible, skull-mounted aiming device to implant DBS electrodes and

MR coils specifically designed to provide optimal imaging during surgery. Their device, ClearPoint, allows surgeons to guide the electrodes under direct MR visualization and patients do not need to be awake to confirm correct placement. ClearPoint was approved by the FDA for clinical use in 2010 and is now being implemented in surgical suites across the nation.

As part of the Program's effort to train the next generation of movement disorder specialists, a year-long fellowship is offered that provides in-depth training in this subspecialty. There have been 18 graduating fellows to date and the majority of them have gone on to positions in academic medicine.



Developing the Next Generation of Deep Brain Stimulators

Groundbreaking scientific work by Philip Starr MD, PhD, director of the Surgical Movement Disorders Program, was nominated for the 2013 B.R.A.I.N. (Breakthrough Research And Innovation in Neurotechnology) Prize awarded by the nonprofit group Israel Brain Technologies. Together with neurologist Jill Ostrem MD and neurophysiologists Coralie de Hemptinne PhD and Nicole Swann PhD, Dr. Starr is working to improve deep brain stimulation (DBS) devices for neurological disorders by incorporating a feedback control mechanism.

Current DBS devices operate with continuous, “open loop” stimulation at high currents, which can induce adverse events and are not responsive to changing symptoms. The large battery needed to supply continuous stimulation also requires frequent changing. Programming to the correct setting for symptom control is done manually by a clinician and is achieved through trial and error.

Analyzing electro-corticographic recordings of neuronal populations, the UCSF investigators found distinctive patterns of brain synchronization in patients with movement disorders. In a neural network, oscillations in electrical potential occur normally. The level of interaction between low and high-frequency activity in field potentials can be measured by what is known as phase-amplitude coupling (PAC). PAC reflects the synchronization of population spiking to cortical rhythms, and, in normal brains, this synchronization is transient and task-specific. In the brains of patients with Parkinson’s disease, PAC over the motor cortex is much higher, with gamma band activity excessively synchronized to the phase of the dominant motor 13-30 Hz (beta) rhythm. (Gamma band activity appears at troughs in the low frequency oscillation in the figure above, left.)

When DBS is introduced, it reduces the excessive PAC that occurs in patients with

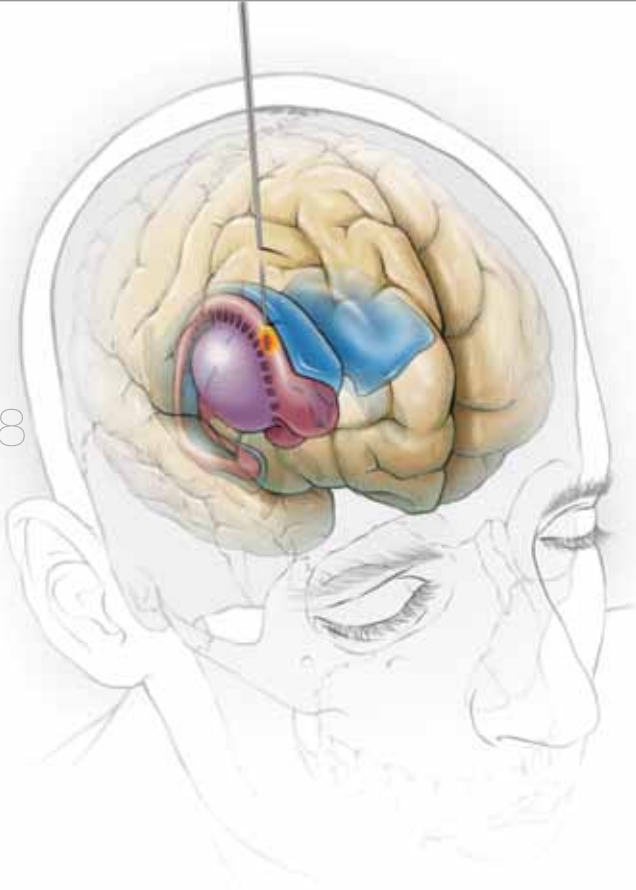
Parkinson’s disease. Drs. Starr and de Hemptinne hypothesize that the electrical pulses from the DBS device may control movement disorder symptoms because they desynchronize the cortex by decoupling population spiking and return neuronal firing to a more normal pattern, less entrained to the motor beta rhythm.

In a new pilot trial, the Surgical Movement Disorders group will implant the Activa® PC+S pulse generator into 10 patients. This new implanted pulse generator stores local field potentials to allow chronic brain recording with wireless, noninvasive data downloading. There are approximately 15 groups worldwide planning to use PC+S in various protocols to treat disorders ranging from epilepsy to obsessive-compulsive disorders. The UCSF Surgical Movement Disorders group is the only group to use it for chronic cortical brain recordings for movement disorders, and on November 1, 2013, was the first group to implant

a chronic multisite brain-recording device in a patient with Parkinson’s disease.

The ultimate goal is to refine the next generation of deep brain stimulators so that they can incorporate the data stored in the implanted pulse generator and create a feedback-controlled system similar to today’s pacemakers. Instead of sending out a constant electrical signal, the device would self-regulate and only put out an electrical pulse when it is needed and symptoms are present.

de Hemptinne C, Ryapolova-Webb ES, Air EL, Garcia PA, Miller KJ, Ojemann JG, Ostrem JL, Galifianakis NB, Starr PA. Exaggerated phase-amplitude coupling in the primary motor cortex in Parkinson disease. **Proc Natl Acad Sci USA** 2013;110(12):4780-5.



Phase I Clinical Trial of Deep Brain Stimulation in Area LC for the Treatment of Tinnitus

UCSF neurosurgeon Paul Larson MD and otolaryngologist Steven Cheung MD have been awarded a U01 grant from the NIDCD (National Institute of Deafness and Communication Disorders) to fund a phase I trial using DBS to treat severe, disabling tinnitus. Ten patients are currently enrolled in the study to establish safety and efficacy, as well as to determine optimal stimulation parameters.

DBS electrodes will be inserted into area LC – an area of the caudate nucleus discovered by Drs. Larson and Cheung to be involved in modulating the perception of auditory hallucinations that occur with tinnitus. In their preliminary experiments, patients undergoing DBS for movement disorders who also had tinnitus reported decreases in the loudness of their tinnitus when DBS stimulation was performed in area LC.

Clinical improvement will be measured by the reduction in patients' tinnitus functional index score – the established measure of tinnitus severity and treatment-related change – and measures of executive functioning. Patients must have tinnitus functional index scores > 50. Secondary measures will be tinnitus handicap index score, tinnitus loudness, and neuropsychiatric symptoms.

Faculty

Pediatric Neurosurgery

Nalin Gupta MD, PhD

Kurtis Auguste MD

Mitchel Berger MD

Corey Raffel MD, PhD

Ronald Shallat MD

Peter P. Sun MD

Pediatric Neuro-Oncology

Anuradha Banerjee MD, MPH

Sabine Mueller MD, PhD

Theodore Nicolaidis MD

Michael Prados MD

Pediatric Radiation Oncology

Igor Barani MD

Daphne Haas-Kogan MD

Penny K. Sneed MD

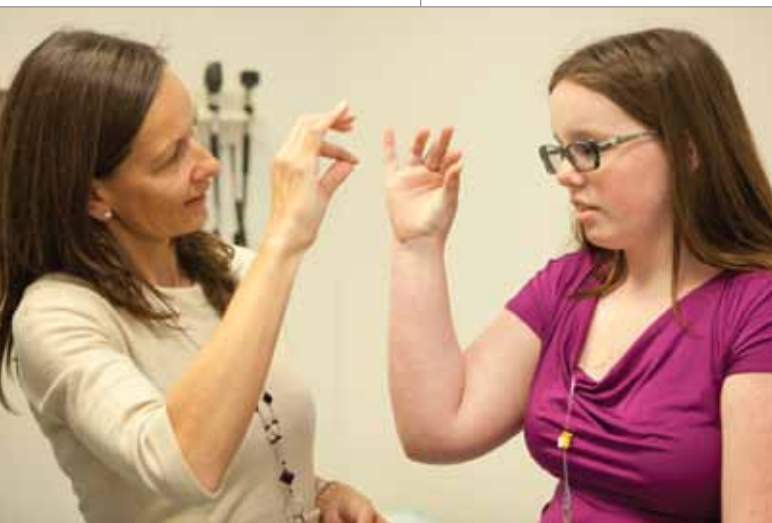Pediatric Neurosurgery

Pacific Pediatric Neuro-Oncology Consortium Grows to Include 10 Hospitals

Children's Hospital of Philadelphia and Nationwide Children's Medical Center are the two newest members of the Pacific Pediatric Neuro-Oncology Consortium (PNOC), offering more families across the United States access to innovative clinical trials.

Formed in 2012 by UCSF pediatric neuro-oncologists Michael Prados and Sabine Mueller, PNOC is a network of children's hospitals that focus on developing personalized medicine for children with brain tumors. PNOC's trials are performed in enriched populations of patients who are most likely to benefit from a therapy based on the molecular signature of their tumor. Visit www.pnoc.us for more information.

30



Co-Project Leader of the Pacific Pediatric Neuro-Oncology Consortium, Sabine Mueller MD, PhD, goes through a neurological examination with a young patient.

Current trials

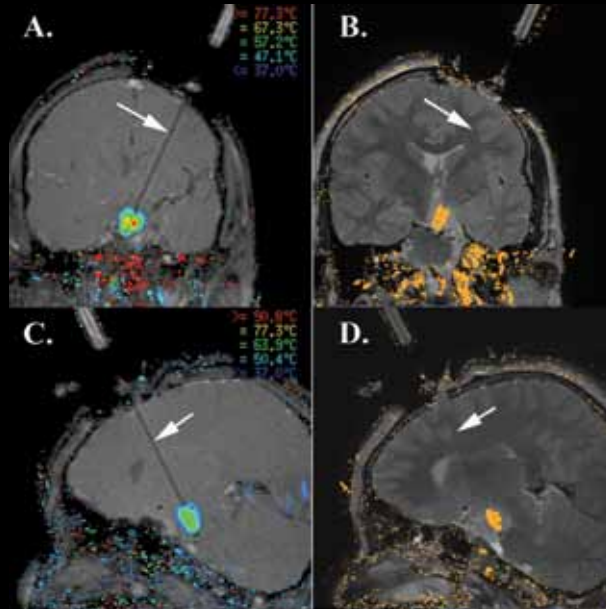
- Phase II Study of Everolimus for Recurrent or Progressive Low-grade Gliomas in Children: Everolimus (RAD001) is an mTOR inhibitor that blocks the PI3K/Akt/mTOR cell-signaling pathway, which is activated in nearly half of grade I and II gliomas. This study will examine whether patients with activated PI3K/Akt/mTOR pathways respond better to treatment with everolimus.

- Safety and Phase 0 Study of Vemurafenib, an Oral Inhibitor of BRAF^{V600E}, in Children With Recurrent/Refractory BRAF^{V600E}-mutant Gliomas: This trial is testing the drug vemurafenib (also called PLX4032) in children with pediatric astrocytomas that have the BRAF^{V600E} mutation. Vemurafenib

works by blocking the activity of BRAF, a key protein in the RAS/RAF/MAPK pathway that is overactive in these tumors. A significant fraction of pediatric astrocytomas contain the BRAF^{V600E} mutation, and this mutation is thought to be vital to tumor maintenance.

- Personalized Medicine Trial for Children with Progressive/Recurrent Gliomas, Including Diffuse Pontine Glioma: Each patient's tumor has an individual molecular profile. In this trial, PNOC investigators will explore the feasibility of linking the molecular profile of a patient's tumor to treatments aimed at the specific aberrations found in that tumor. This may include combination therapies aimed at multiple dysregulated pathways to maximize efficacy and improve survival for children with recurrent glioma.

During laser surgery for pediatric epilepsy, thermal maps (A, C) allow surgeons to monitor the temperature at the target and surrounding tissue, while tissue ablation maps (B, D) show the extent of the abnormal tissue being destroyed. (Arrows: laser fiber)



Targeted Laser Surgery Now Available to Treat Epilepsy in Pediatric Patients

Adding to a comprehensive list of traditional open surgical techniques, as well as device implantation (e.g., vagal nerve stimulators), the pediatric neurosurgery team at UCSF is currently exploring the use of a laser ablation technique to eliminate seizure foci. This approach may not only improve upon current surgical options but may also provide a new option for patients for whom surgery is excessively dangerous.

This new approach shares the common goal of well-established epilepsy procedures: eliminate the source of seizure onset. Accomplishing this through standard surgery can carry with it some risk. Access to seizure foci typically requires

a craniotomy and exposure of the brain. Though rare, the risks of bleeding, infection, and tissue damage exist. Depending on the nature of the surgery, incisions can require significant pain medication during the healing process and this often translates into time spent in both the intensive care unit and ward. Later, in the event that seizures persist or return, additional surgery may be necessary and poses the additional challenge of scarred anatomy.

Laser ablation is a new minimally invasive option that involves a laser fiber inserted into a small hole in the skull. The tip of the laser is then guided to a predetermined target by MRI. Over the course of several minutes, the

laser heats and destroys the area of abnormal tissue from within and the treatment's progress is measured in real time with thermal imaging. Thermal safeguards are assigned to surrounding tissue immediately prior to the onset of therapy so that once a temperature threshold is reached, the device shuts off and neighboring structures are left unharmed. Patients go home 24 to 48 hours after treatment and cessation of seizure activity is often immediate. Physicians at UCSF are investigating how this technology can be applied to a wide range of disorders including epilepsy, brain tumors, and movement disorders.

Faculty

Pediatric Research Laboratories

Arturo Alvarez-Buylla PhD
Developmental neuroscience;
stem cell neurobiology

Nalin Gupta MD, PhD,
Co-director,
Pediatric Brain Tumor
Research Center

Pediatric brain tumor
biology; cell-cell
interactions;
drug-delivery strategies

C. David James PhD,
Co-director,
Pediatric Brain Tumor
Research Center

Molecular biology of
CNS cancer; rodent
model testing of
experimental therapies

Theodore Nicolaides MD
BRAF oncogenesis in
pediatric CNS tumors

Anders Persson PhD
Neural precursors of
pediatric brain tumors

Claudia Petritsch PhD
Brain cancer stem cells;
asymmetric stem cell
division; novel tumor
suppressor genes

Joanna Phillips MD, PhD
Neuropathology;
interaction between
tumor cells and
microenvironment

David Rowitch MD, PhD
Central nervous
system development and
tumorigenesis

William Weiss MD, PhD
Molecular basis of
medulloblastoma

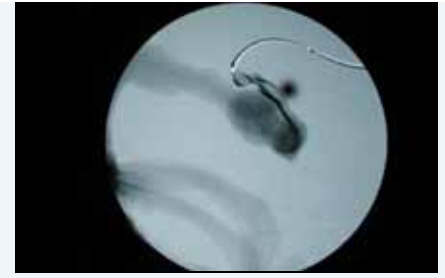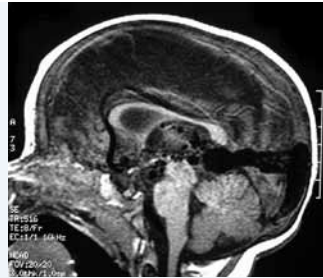Cerebrovascular Disorders in Children

Although rare, vascular anomalies and diseases do occur in children and if not recognized can cause permanent neurologic deficit and substantial long-term disabilities. There are different types of vascular lesions including arteriovenous malformations (AVM), cerebral aneurysms, moyamoya disease, arterial dissection, and strokes.

Different types of conditions occur at different ages. For example, in infants a number of congenital anomalies can occur, often with abnormal vascular shunts forming between the arterial and venous vascular distributions. One specific example is the vein of Galen aneurysm, which can be very large and cause heart failure and affect normal brain development.

In older children, the most common type of lesion is the arteriovenous malformation, and aside from trauma, is the most common cause of intracranial hemorrhage. These malformations can occur in any part of the brain and depending on their size and location, are treated with a variety of tools.

An infant with a large vein of Galen malformation (seen in the sagittal MR image at left) was successfully treated with a minimally invasive surgical procedure. Interventional neuroradiologists threaded a catheter into the malformation and coiled platinum wires within it to create a plug (seen in the angiogram at right).



Multidisciplinary Treatment

The choice of treatment depends on the condition, age of the child, and whether it is producing symptoms. There is a broad range of treatment including medications, interventional techniques, surgery, and focused radiation treatment (radiosurgery).

Interventional Neuroradiology

The interventional neuroradiologists at UCSF have pioneered the endovascular treatment, both from an arterial and venous route, of infantile vascular malformations, such as vein of Galen malformations. In

young children, often multiple treatment sessions are required to achieve complete obliteration of the lesion. If the lesion is asymptomatic at birth, treatment may be delayed until the child reaches two to three years of age.

Gamma Knife Radiosurgery

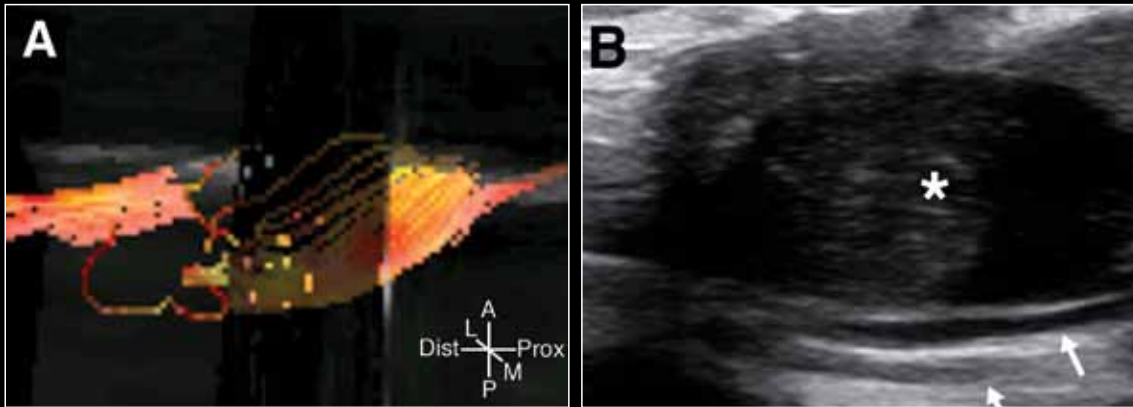
In children, Gamma Knife radiosurgery is used to treat deep AVMs or very large AVMs as a prelude to future surgery. Because the long-term effects of radiosurgical treatment are not well defined in very young children, treatment is rarely considered for those under 5 years of age. For large AVMs, several

radiosurgical sessions are used to reduce the amount of radiation to the normal brain. The team at UCSF has over 15 years of experience treating complex and large AVMs in children.

Microsurgery

For many vascular lesions, the treatment of choice is surgical obliteration or excision. For conditions where blood flow to the brain is reduced, as in moyamoya disease, revascularization procedures can improve blood flow to the brain and reduce the likelihood of future strokes or hemorrhage.

Center for Management and Surgery of Peripheral Nerve Disorders



A) MR tractography in a patient with a right median nerve arm tumor in longitudinal plane demonstrating nerve fibers (orange color) coursing along the postero-medial aspect of the tumor. B) Corresponding high-resolution ultrasound image (longitudinal plane) demonstrating nerve fibers (white arrows) corresponding to the location identified on MR tractography.

A = anterior, P = posterior, M = medial, L = lateral, Dist = distal, Prox = proximal.

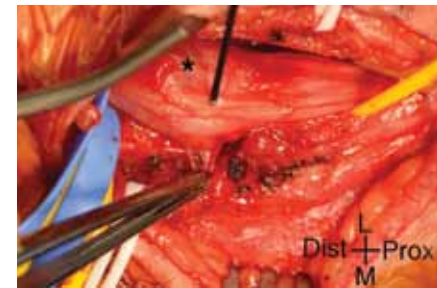
Expanding Applications for Ultrasound in Peripheral Nerve Surgery

MRI is the standard tool used for preoperative diagnosis of the majority of neurosurgical conditions. However, recent work by Michel Kliot MD, chief of peripheral nerve surgery, has concluded that ultrasound may be a faster, reliable and more cost-effective alternative in certain cases for preoperative planning for peripheral nerve disorders. Advances in ultrasound technology are allowing surgeons to visualize peripheral nerves as small as 2 mm in diameter and provide a good map of adjacent anatomical structures.

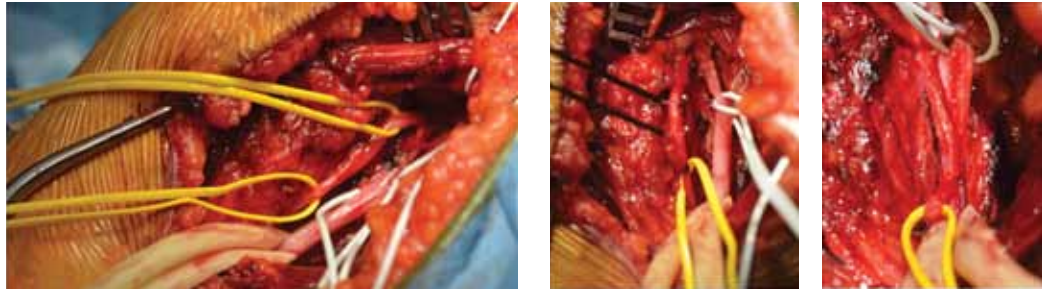
Magnetic resonance neurography studies provide superior detail of damaged nerves with visualization of axons using DTI protocols, but only give static images that do not take into account any changes in limb position before and during surgery that might change the position of the nerve or an associated mass relative to surrounding structures. Portable ultrasound machines can be used in the operating room to guide the surgeon toward the nerve by the most direct route, requiring smaller incisions and reducing

surgical time. Ultrasound may be especially useful when nerves have been severed or transposed and for localizing deeply situated peripheral nerve tumors. Ultrasound is now routinely used at UCSF to evaluate patients with peripheral nerve disorders in the preoperative, intraoperative, and postoperative settings.

Gofeld M, Bristow SJ, Chiu S, Kliot M. Preoperative ultrasound-guided mapping of peripheral nerves. *J Neurosurg* 2013;119(3):709-13.



Intraoperative photography following exposure of the right median nerve tumor(*) as viewed from the antero-medial aspect of the arm. The stimulator tip is contacting the intact nerve fascicles on the postero-medial aspect of the tumor. M = medial, L = lateral, Dist = distal, Prox = proximal.



Technical Breakthroughs in Peripheral Nerve Surgery: Side-to-Side Anastomosis

UCSF neurosurgeons have reported the first case of muscle reinnervation following traumatic nerve injury using a new surgical technique called side-to-side anastomosis. By placing an intact nerve alongside a severely damaged nerve and creating two small superficial incisions in each, new axons can sprout from the healthy nerve to the site of injury.

In this case report, biceps muscle function in a patient who suffered a brachial plexus injury had not recovered 9 months after

initial surgery. Using side-to-side anastomosis of the intact median nerve and distal musculocutaneous nerve, the biceps muscle was reinnervated by axons from both the donor and injured nerves. Electrodiagnostic studies demonstrated that the biceps muscle responded to both the median and musculocutaneous nerves at 9 months after the second surgery. Combined activation of the biceps muscle by both nerves, but not each nerve alone, produced elbow flexion at greater than antigravity strength.

This new nerve repair technique has the added advantage of minimizing damage to the donor intact nerve while preserving continuity of the injured nerve so as to allow recovery through regeneration of axons along the original nerve pathway.

Cage TA, Simon NG, Bourque S, Noss R, Engstrom JW, Ralph JW, Kliot M. Dual reinnervation of biceps muscle after side-to-side anastomosis of an intact median nerve and a damaged musculocutaneous nerve. *J Neurosurg* 2013;119:929-33.

34

Exploring Quiescence in Neurofibromas: ‘Thinking Outside the Box’

Neurofibromas display a startling range of clinical behaviors – they may lie dormant for years or even regress; grow slowly and consistently over time; or undergo rapid malignant transformation with metastatic spread. The underlying mechanisms that drive these variable growth rates are poorly understood, but if elucidated could allow for better treatment planning and new therapeutic targets.

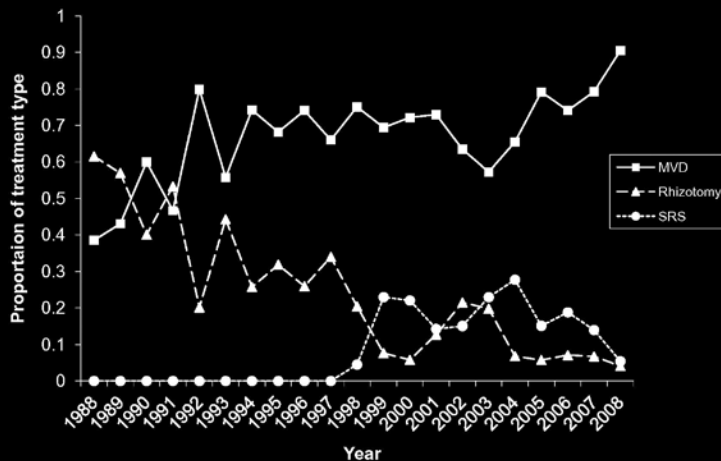
In the first article of “Thinking Outside the Box” – a new section of *Surgical Neurology International* – Michel Kliot MD and colleagues propose that oncogenes (such as mutated Raf and Ras) may induce senescence in neurofibromas by triggering a negative feedback response to halt tumor growth. Further mutations, possibly caused unintentionally by mutagenic agents such as chemotherapeutics or radiation, could

inactivate important cell-cycle checkpoints that suppress tumor growth, raising questions about the use of those treatments for tumors not shown to be aggressive.

Dr. Kliot and his UCSF colleagues Joe DeRisi PhD, Tarik Tihan MD, and Dan Faden MD are planning studies to monitor growing and non-growing neurofibromas in individual patients with neurofibromatosis type 1, where the NF1 germline mutation is the same in all cells. These studies may provide insight into the checkpoints that must remain intact to curb activated oncogenic pathways.

Kliot T, Ince Y, Tihan T, Wilson M, Kliot M. To grow or not to grow, that is the question. *Sug Neurol Int* 2013;4(Suppl 1):S407-10.

Surgical Pain Management Program



MVD = microvascular decompression, SRS = stereotactic radiosurgery.

Trends in surgical treatment for trigeminal neuralgia demonstrate an increasing preference for microvascular decompression over other approaches. Reprinted from Journal of Clinical Neuroscience, vol 20 /edition 11, Wang DD, Ouyang D, Englot DJ, Rolston JD, Molinaro AM, Ward M, Chang EF, Trends in surgical treatment for trigeminal neuralgia in the United States of America from 1988 to 2008, pp.1538-1545, Copyright (2013), with permission from Elsevier.

Current State of Practice for Trigeminal Neuralgia

Trigeminal neuralgia, also called tic douloureux, is a rare neurological disease that causes intense burning or stabbing pain along the side of the face. It is usually caused when the trigeminal nerve is being compressed by an artery or a vein, but can also be present with no apparent cause. It is frequently misdiagnosed as a dental or jaw problem or as a psychological disorder. Once correctly diagnosed, there are several medical and surgical treatment options to reduce or relieve the debilitating pain caused by this disease.

Although there are no results from prospective clinical trials comparing efficacy of the various surgical techniques

for trigeminal neuralgia, members of the Surgical Pain Management Program have recently analyzed clinical patterns in the medical community to better understand how treatment decisions for patients with this disease are being made. They hope to use these data to better inform patients and other physicians about treatment options and expectations for resolution of symptoms.

Trends in surgical treatment for trigeminal neuralgia

Microvascular decompression (MVD), radiosurgery, and percutaneous rhizotomy are the most common surgical treatments for trigeminal

neuralgia. A recent UCSF study of clinical practice patterns between 1998 and 2008 has shown that MVD has become increasingly favored over rhizotomy and stereotactic radiosurgery. MVD has the lowest rates of pain recurrence – 64-74% of patients are pain-free at 10 years. However, it also has the highest rates of complications and is therefore more likely offered to younger patients who are inherently at less surgical risk. MVD also spares the nerve and, unlike rhizotomy, has low rates of postoperative sensory loss.

The use of stereotactic radiosurgery peaked in 2004. It is associated with

the lowest rates of efficacy and highest rates of pain recurrence, but is the least invasive procedure and can be repeated.

Private insurance was more likely to pay for MVD, whereas Medicare paid for more rhizotomy and radiosurgical procedures. Tracking the patterns of care and outcomes for these patients will become especially important as insurance and healthcare policies begin to change at the national level.

Wang DD, Ouyang D, Englot DJ, Rolston JD, Molinaro AM, Ward M, Chang EF. Trends in surgical treatment for trigeminal neuralgia in the United States of America from 1988 to 2008. *J Clin Neurosci* 2013;20(11):1538-45.

Percutaneous Treatment for Trigeminal Neuralgia

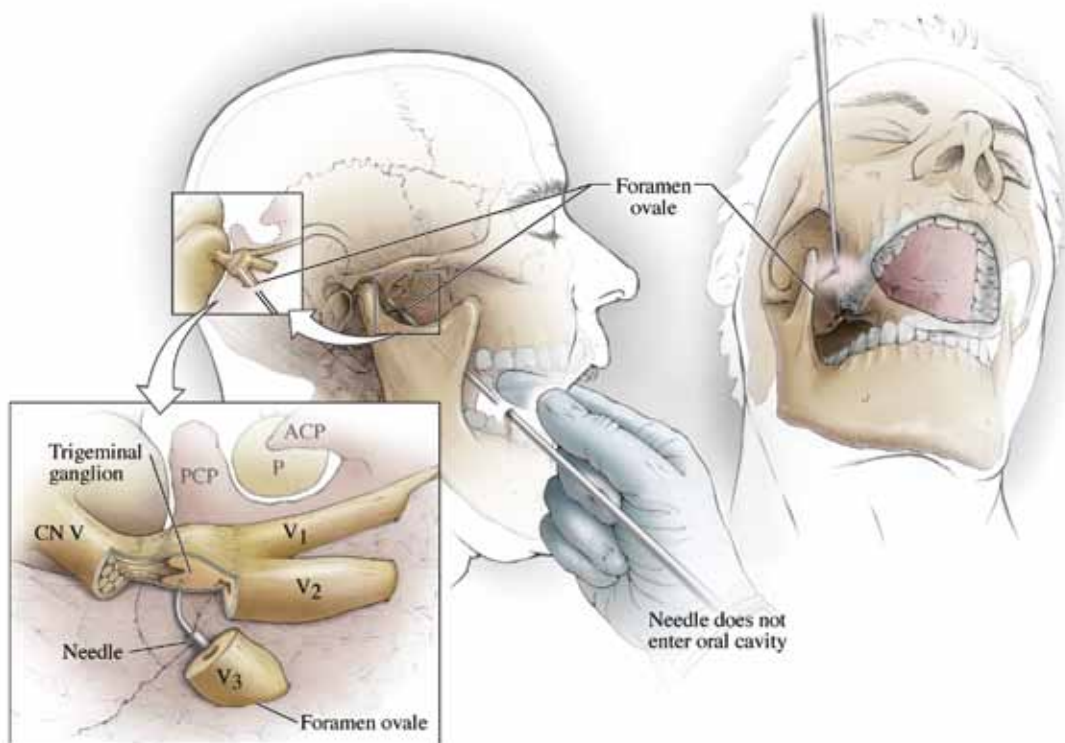
Percutaneous treatments for trigeminal neuralgia were some of the earliest treatments developed for this disease and involve injuring the pain fibers in the trigeminal nerve. The most common types of percutaneous treatment are balloon compression, glycerol rhizotomy, and radiofrequency thermocoagulation. They are all generally safe and effective, but are associated with higher rates of pain recurrence

than other treatments, such as microvascular decompression. Despite the higher rate of pain recurrence, percutaneous treatment may still be the best option for select patients, such as those with no clear nerve compression and atypical facial pain.

Each percutaneous procedure has a different mechanism of injuring the trigeminal nerve, and proper patient selection is the most important factor in clinical outcome. Patient preference, underlying pathophysiology of the

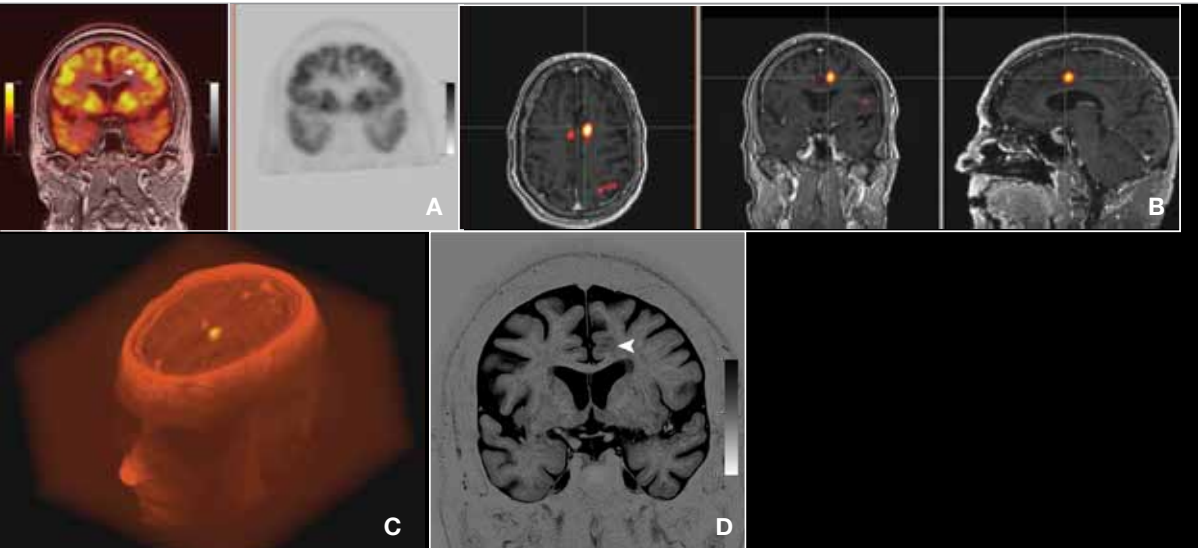
disease, typical vs. atypical pain, and the surgeon's familiarity and skill with each procedure should all be included in the decision algorithm. Higher hospital and surgeon volume are independently tied to better clinical outcomes and fewer complications.

Cheng JS, Lim DA, Chang EF, Barbaro NM. A review of percutaneous treatments for trigeminal neuralgia [published online ahead of print September 23, 2013]. *Neurosurgery*. doi: 10.1227/NEU.000000000000168.



Radiofrequency thermocoagulation for trigeminal neuralgia.

Epilepsy



Epilepsy Surgery Case 1: Multimodality image registration and advanced analysis of functional imaging reveals cryptic focal cortical dysplasia in this 57-year-old male with nearly life-long frontal lobe epilepsy long believed to be non-surgical due to negative EEG and absence of a lesion on MRI. Re-evaluation with high-

resolution FDG-PET raises suspicion of a focal metabolic defect in the left mesial frontal region. After coregistration to MRI (A), and confirmation that metabolism decrease is in an area of cortical grey matter as opposed to an enlarged sulcal space that would cause an artifactual defect, suspicion of epileptogenic tissue is increased. Next,

an ictal SPECT with special subtraction, statistical mapping, and finally coregistration to MRI (B and C) reveals a marked focal increase in seizure-related blood flow in the same region as the suspicious PET defect. Re-interpretation of MRI with special high-resolution MRI sequences in the region of interest indicated by the

PET and SPECT (D) shows a subtle change in juxtacortical signal suggestive of focal cortical dysplasia. Following surgical removal of this region, the patient became free of disabling seizures and microscopic histopathology showed severe Type IIb cortical dysplasia.

37

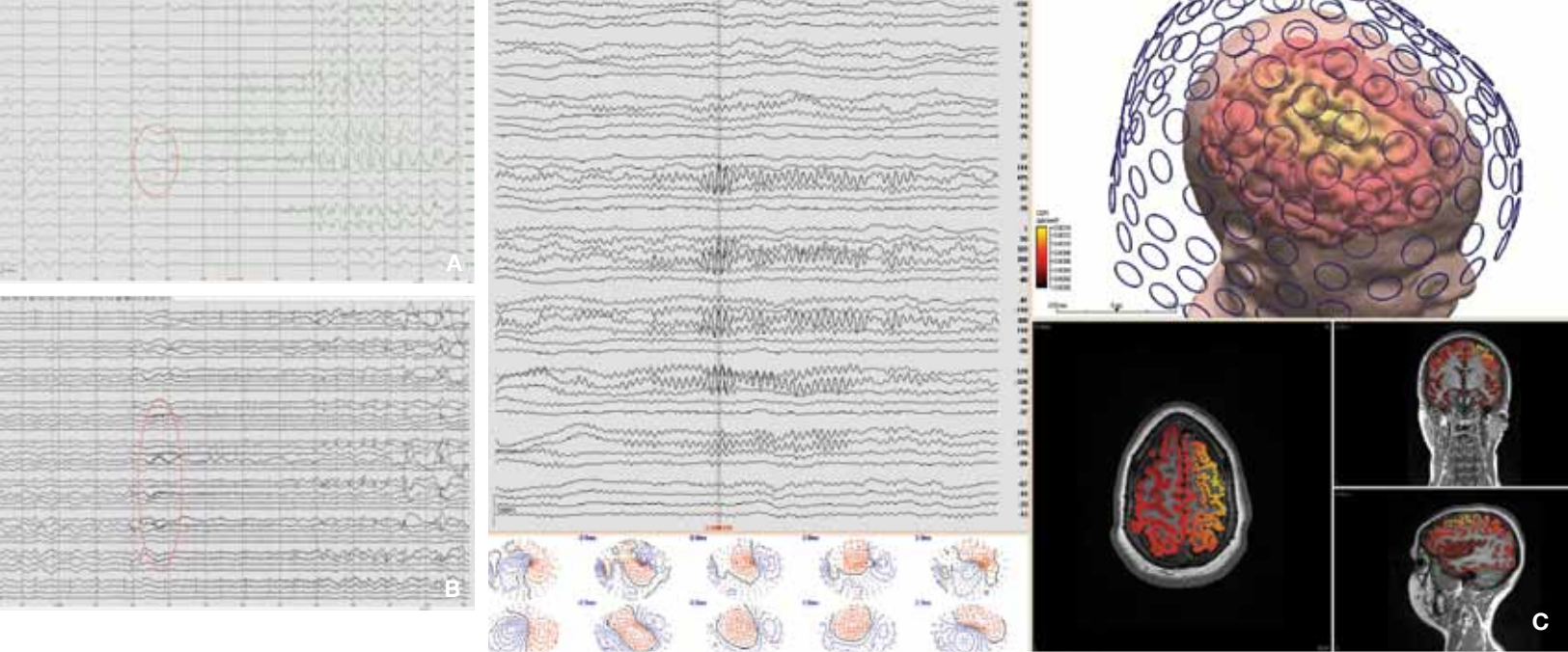
Renowned Epileptologist Robert Knowlton MD Joins the Surgical Epilepsy Program

Internationally regarded epilepsy expert Robert Knowlton MD has joined the UCSF Epilepsy Center. He specializes in diagnosing complex cases of epilepsy, such that those that have no clear origin, and in identifying patients who could be successfully treated with surgery. It has been clearly shown that surgery is underutilized in the treatment of epilepsy, and UCSF is leading the effort to offer more patients a permanent option for a life free from seizures.

Localizing Occult Foci and Surgery for Non-lesional Epilepsy

Often, locating the source of epileptic seizures is not as straightforward as most clinicians would like. Thirty percent of patients with epilepsy are diagnostically negative and 20%

of MRI results that are positive for epilepsy are misleading. The result is that many patients who have been told that they have “inoperable epilepsy” may actually be good surgical candidates. Even in those patients with foci localized to functional cortex, there may still be a surgical option in which function can be preserved. Dr. Knowlton has a special interest in identifying these “occult” epileptogenic foci that require combining the results of a variety of tests to locate. When the origin of the seizures has been pinpointed, Dr. Knowlton collaborates with Chief of Adult Epilepsy Surgery, Edward Chang MD, to determine if it can be resected.



38
Epilepsy Surgery Case 2: Magnetic source imaging using real-head forward modeling and special high-frequency signal analysis localizes the source of epileptic seizures in an otherwise healthy 14-year-old female patient with medically intractable partial

seizures since age 4. Based on non-localizing EEG (both between and during seizures) and a normal MRI, the patient had not been considered a candidate for surgical treatment. EEG at the onset of one of the patient's daily partial seizures (A) is interpreted as non-localized

(most likely arising from both hemispheres at the same time). MEG recorded at the same time (B) reveals both a lateralized seizure pattern (right side), and an intermixed focal "fast activity" pattern that is more specific for seizure onset localization in the right frontal lobe.

Advanced source modeling (distributed current density source) using the patient's own MRI (C) allows 3D localization of the fast MEG seizure pattern, allowing the patient to proceed with further surgical evaluation and treatment.

Epilepsy Imaging Initiative

Perhaps the most important part of an accurate diagnosis is multimodality imaging. As part of the Center's new Epilepsy Imaging Initiative, specialists at the UCSF Epilepsy Center combine all of the most advanced image processing techniques to form a larger, comprehensive picture of what is happening for an individual patient. This includes:

- ictal SPECT (Single Photon Emission Tomography)
- Functional MRI
- Diffusion Tensor Imaging
- Positron Emission Tomography
- High-density EEG and Video EEG
- Magnetoencephalography
- 3T and 7T MRI

Quality-of-Life Studies Show Patients Prefer Surgery

Decision analysis studies have shown that when presented with the risks and benefits of epilepsy surgery, patients overwhelmingly prefer surgery to medication if seizure freedom can be achieved with no complications. Many patients with neocortical epileptic foci will accept minor morbidity, particularly minor motor deficits, and still opt for surgery over life-long medication if seizure control can be achieved. Although these are small, early studies of patient preferences, the results make a compelling argument for early surgical evaluation of patients whose seizures cannot be adequately controlled with medication, even if the epileptic focus is thought to overlap with eloquent cortex.

Observational Study to Follow Patients Receiving Laser Ablation Surgery for Epilepsy

Minimally invasive laser ablation surgery is a relatively new treatment for epilepsy, and in select patients has the potential to halt seizures with minimal damage to surrounding tissue and fewer risks than open surgery. Patients undergoing laser ablation for mesial temporal lobe epilepsy at UCSF will be followed for two years to gather data on durability and long-term effects of treatment. The primary goal will be to determine

if patients are still seizure free and to compare the results to those of patients who undergo anterior temporal lobectomies at two years.

Robert Knowlton MD will serve as principal investigator of the study, which will also evaluate quality-of-life measures and look to determine whether there are fewer cognitive and visual defects following laser ablation than standard surgery.



Potential Drug Discovered for Dravet Syndrome

Scott Baraban PhD and researchers in his laboratory have discovered that the antihistamine clemizole can prevent seizures in a zebrafish model of Dravet syndrome. This rare genetic disorder manifests in early childhood and is characterized by daily seizures, as well as cognitive and social deficits.

Dr. Baraban's zebrafish have a mutation identical to the one that causes Dravet syndrome and were used to screen a library of existing FDA-approved compounds – including clemizole – to see if any would prove effective against the disease's

symptoms. The mechanism by which clemizole blocks seizures is unknown. Ten other antihistamines were screened, but none of them prevented seizures.

Senior staff research associate Matthew T. Dinday BA and postdoctoral fellow Gabriela A. Hortopan PhD were co-authors of this study, published in *Nature Communications*.

Baraban SC, Dinday MT, Hortopan GA. Drug screening in *Scn1a* zebrafish mutant identifies clemizole as a potential Dravet syndrome treatment. *Nat Commun* 2013;4:2410.

Transplanted Progenitor Cells Cure Epilepsy in Mice

The laboratories of Scott Baraban PhD and Arturo Alvarez-Buylla PhD have published the first report demonstrating that progenitor cells transplanted into the hippocampi of mice with mesial temporal epilepsy can halt or significantly reduce

seizures. In their experiments, progenitor cells derived from the medial ganglionic eminence region of the brain migrated from the injection site and differentiated into functional interneurons. Interneurons secrete the neurotransmitter GABA,

which inhibits the aberrant excitatory circuits in the brain causing seizures.

Hunt RF, Girskis KM, Rubenstein JL, Alvarez-Buylla A, Baraban SC. GABA progenitors grafted into the adult epileptic brain control seizures and abnormal behavior. *Nat Neuosci* 2013;16(6):692-7.

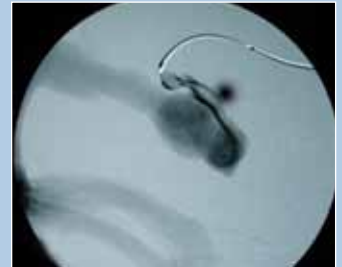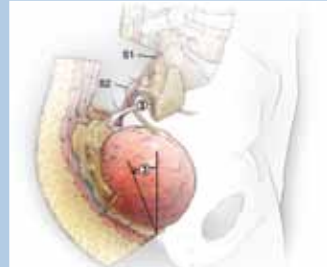
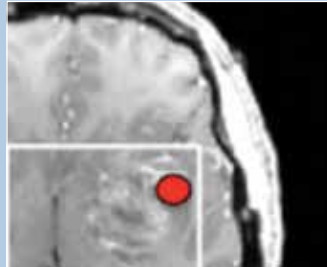
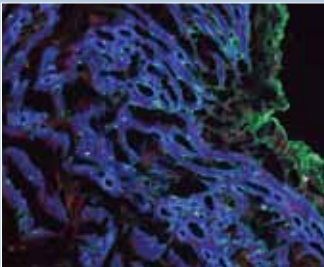
UCSF Department of Neurological Surgery
505 Parnassus Avenue, 779 M
San Francisco, CA 94143-0112

Nonprofit Org.
U.S. Postage
PAID
University of
California
San Francisco

UCSF

University of California
San Francisco

advancing health worldwide™



University of California
San Francisco

UCSF

Neurological Surgery